

CLI GLOBAL COMPENDIUM

THE GLOBAL VOICE OF CRITICAL LIMB ISCHEMIA

5th Annual Amputation Prevention Symposium Hosts Nation's Largest Gathering of Clinicians Dedicated to Preventing CLI Amputations

J.A. Mustapha, MD; Larry J. Diaz-Sandoval, MD; Fadi Saab, MD
From Metro Health Hospital, Wyoming, Michigan.



J.A. Mustapha, MD

The 5th annual AMPutation Prevention Symposium (AMP) was held in Chicago from August 12 to 15, 2015. This year's record attendance included nearly 800 participants from 19 countries, convening for the nation's only medical conference focused on preventing lower-limb amputation in patients with critical limb ischemia (CLI). Attendees included those involved with peripheral vascular interventions: vascular and general surgeons, interventional and general cardiologists, primary care physicians, interventional

radiologists, podiatrists, wound care specialists, nurses, vascular technicians, and cardiac cath technologists. They interacted with the world's most respected leaders and pioneers in critical limb ischemia therapy and gained knowledge and strategies to help prevent lower limb amputations in patients. AMP 2015 featured presentations from leading CLI experts with 4 days of high-level education, hands-on workshops, and tools and technologies used for access, intervention, and closure of CLI cases.

SAVING LIMBS IS THE NUMBER ONE PRIORITY

The AMP Symposium was born due to an unmet need for education and technologies to address the critical health issue of CLI. AMP gives physicians the opportunity to share strategies with the very best minds in this field, embrace innovation, and learn about the vital role emerging therapies play in preventing amputations. It has become our personal mission to see amputations due

Continued on page 31

Lessons Learned in Treatment of Calcified SFA and Popliteal Lesions

Marianne Brodmann, MD
From the Division of Angiology, Medical University Graz, Austria.



Marianne Brodmann, MD

So-called complex lesions within the femoropopliteal vascular territory include long lesions of more than 15 cm in length or heavily calcified lesions. The last update of the TASC II criteria recommend a primarily surgical approach for these lesions.¹ But the evolving endovascular techniques allow the recanalization of such heavily calcified complex lesions and even improve patency. Therefore more and more endovascular specialists go for endovascular reopening techniques first. But how can we overcome the issue of calcium burden in superficial femoral artery (SFA) and popliteal artery disease?

The first step is an improvement in devices, especially guidewires and crossing catheters, which improve the crossing of those usually

chronic totally occlusions (CTOs). Many companies have come to the market with dedicated CTO crossing devices. But not only have devices improved, also the way of crossing the lesions has changed. If antegrade crossing is not possible as a first step, a retrograde approach from the foot of at least below-the-knee level is used more frequently. After a successful crossing, the main problem that remains is the calcium burden in the vessel wall.

Plain old balloon angioplasty (POBA) does not give us good results. In contrast, it proved to be worse than bare metal stenting (BMS). The RESILIENT trial showed at 12 months a freedom from target

Continued on page 22



Rise Above



With the Latest in PTA Balloon Innovation



CHOCOLATE® PTA Balloon Catheter Designed to Provide:

- Controlled, Predictable, Uniform Inflation.
- Reduced "Dog-Boning."
- Concentric Secondary Profile.



SABER™ PTA Dilatation Catheter

- More 0.18" OTW Sizes Available.
- More Crossability.
- More Power. More Control.

For more information contact your Cordis Sales Representative, call 800.327.7714 or email CLI@cordis.com

Important Information: Prior to use, refer to the "Instructions For Use" supplied with these devices for indications, contraindications, side effects, suggested procedure, warnings and precautions.


CAUTION: Federal (USA) law restricts these devices to sale by or on the order of a physician. See package insert for full product information.

Cordis Corporation ©Cordis Corporation 2014. CHOCOLATE® is a trademark of TriReme Medical, LLC. All rights reserved. Third party trademarks used herein are trademarks of their respective owners.

155-8615A-2 23367 10/14

Tibial Interventions: Technical Factors That Matter

John H. Rundback, MD; Kevin "Chaim" Herman, MD; Amish Patel, MD
From the Interventional Institute, Holy Name Medical Center, Teaneck, New Jersey.



John H. Rundback, MD

Critical limb ischemia (CLI) is marked by multilevel peripheral arterial disease (PAD), of which the infrapopliteal component is the most influential and arguably the most challenging to treat. Isolated tibial occlusive disease is highly prevalent in diabetics and chronic kidney disease patients, representing almost half of the population with PAD. Due to an evolution of technology, experience, and device options, tibial intervention is increasingly (although still insufficiently) performed to treat ischemic rest pain and ulcerations that would otherwise be poorly amenable to surgical bypass and often result in limb loss. There are several important technical considerations to optimize the results of endovascular

tibial therapy. Among these are balloon sizing, specific device strategies, and angiographically assessed treatment targets and endpoints.

BALLOON SIZING

A review of the impact of balloon sizing on arterial lumen after percutaneous transluminal angioplasty (PTA) is largely an antediluvian reflection. The principal mechanism of PTA is intimal and medial dissection, with undermining of elastic tissue in the least atherosclerotic portions of the artery, or multidimensional fragmenting of circumferential, noncompressible plaque. Remodeling and endothelialization in response to physiologic flow results in a maintained luminal gain.¹ Conceptually, underdilation will inadequately stretch and dehisc structural tissues, thereby impairing luminal expansion, while overdilation will increase the risk of flow-limiting dissection, rupture, spasm, and barotrauma (see figure). Early data in cadaveric models supported a greater amount of intimal-medial disruption with oversized balloons, which was also accompanied by deformation and necrosis of the medial smooth muscle cells that benefited acute angioplasty results.¹ However, other factors also affect acute PTA results, most notably the phenomenon of viscoelastic recoil (and corresponding later uniform geometric arterial contraction). Hanet et al studied 28 coronary arteries and found better acute results with smaller balloons

than larger balloons due to a greater amount of immediate recoil with the oversized PTA. However, at 24 hours, overall luminal improvement was better in the overstretch cohort.² This phenomenon of early recoil after PTA has been observed in tibial arteries as well, with an approximately one-third loss of the flow channel 15 minutes after angioplasty when compared to immediately post treatment.³ Early pathologic analysis from surgically excised human angioplasty segments has shown that arteries that achieve greater initial luminal caliber have lower restenosis rates.⁴ Collectively, these findings suggests that an overstretch injury produced by larger rather than smaller diameter balloons during tibial angioplasty may result in better patency.

DEVICE STRATEGIES

While PTA remains the primary method for endovascular tibial revascularization, other strategies may have unique advantage in certain settings. In the tibial arteries, intimal and plaque calcification is highly prevalent, potentially limiting uniform balloon expansion and mitigating the "controlled" arterial injury desired from angioplasty. Atherectomy has been shown to alter plaque and vessel morphology, effectively debulking luminal calcium. The best evidence to date is with the use of orbital atherectomy (OA).

Continued on page 12

EDITORIAL

J.A. MUSTAPHA, MD, FACC, FSCAI

Clinical Editor
Director, Cardiovascular
Catheterization Laboratories
Director, Endovascular Interventions
Director, Cardiovascular Research
Metro Health Hospital, Wyoming, MI
Clinical Assistant Professor of Medicine
Michigan State University CHM and
COM, East Lansing, MI
Marianne Brodmann, MD
Guest Editor; Graz, Austria

Jeff Martin, Publisher
Jennifer Ford, Managing Editor
Vic Geanopoulos, Creative Director
Elizabeth Vasil, Production Manager

EDITORIAL CORRESPONDENCE:

Jennifer Ford, Managing Editor
HMP Communications
83 General Warren Blvd.
Malvern, PA 19355
Tel.: 800-237-7285 Fax: (610) 560-0503
jford@hmpcommunications.com

SCIENTIFIC ADVISORY BOARD

GEORGE ADAMS, MD
Garner, NC

GARY ANSEL, MD
Columbus, OH

TONY DAS, MD
Dallas, TX

LAWRENCE GARCIA, MD
Boston, MA

OSAMU IIDA, MD
Amagasaki City, Japan

D. CHRIS METZGER, MD
Kingsport, TN

CONSTANTINO S. PENA, MD
Miami, FL

DIERK SCHEINERT, MD
Leipzig, Germany

ANDREJ SCHMIDT, MD
Leipzig, Germany

RAMON VARCOE, MBBS, MS
Sydney, Australia

RENU VIRMANI, MD
Gaithersburg, MD

THOMAS ZELLER, MD
Bad Krozingen, Germany

Published in collaboration with



Editor's note: Articles in this supplement to Cath Lab Digest did not undergo peer review.

TABLE OF CONTENTS

5th Annual Amputation Prevention Symposium Hosts Nation's Largest Gathering of Clinicians Dedicated to Preventing CLI Amputations	1
Lessons Learned in Treatment of Calcified SFA and Popliteal Lesions	1
Tibial Interventions: Technical Factors That Matter	3
Learning From the Best: Imaging Modalities for Infrapopliteal Calcified Lesions	4
Three Key Considerations in the Treatment of Critical Limb Ischemia ...	6
Does Endovascular Revascularization Ruin Surgical Options Above and Below the Knee?	8
Drug-Coated Balloon Angioplasty for the Treatment of Calcified Tibial Vessels.....	10
The Use of Alternative Access in Calcified Tibial Vessels.....	14
Selecting the Appropriate Endpoints in Critical Limb Ischemia Trials: More Challenging Than It May Appear.....	16
CLI Affects More Than the Legs: Upper-Extremity	
Critical Limb Ischemia	18
Amputation or Not for Ruthurford Class VI Patients: Is It Final?	20
Abstracts From the 5th Annual Amputation Prevention Symposium.....	22

©2015, Critical Limb Ischemia Compendium, LLC (CLIC). All rights reserved. Reproduction in whole or in part prohibited. Opinions expressed by authors, contributors, and advertisers are their own and not necessarily those of Critical Limb Ischemia Compendium or the editorial staff. Critical Limb Ischemia Compendium is not responsible for accuracy of dosages given in articles printed herein. The appearance of advertisements in this journal is not a warranty, endorsement or approval of the products or services advertised or of their effectiveness, quality or safety. Critical Limb Ischemia Compendium disclaims responsibility for any injury to persons or property resulting from any ideas or products referred to in the articles or advertisements.

Content may not be reproduced in any form without written permission. Contact jihad.mustapha@metrogr.org for rights and permission.

Learning From the Best: Imaging Modalities for Infrainguinal Calcified Lesions

George A. Pliagas, MD, FACS, FRCS(C)



George A. Pliagas, MD, FACS, FRCS(C)

The array of available treatment options for patients with peripheral vascular disease has undergone significant changes over the past 10 years. What has remained the same is that we still require appropriate knowledge of the patient's vascular inflow and outflow and the location and length of the lesion.^{1,2}

From an endovascular perspective, the aim is to obtain as much clinical and imaging information about the vascular bed prior to taking the patient to the angiographic suite. A therapeutic plan prior to angiography is necessary in setting up the room for the various access options at our disposal.

Preoperative imaging can help guide revascularization efforts. Being aware of the occlusions or types of lesions enables better planning. The diagnostic selective angiogram will be helpful, but it is definitely advantageous to troubleshoot ahead of time, especially when calcium is involved. Preoperative imaging modalities include duplex ultrasound, computerized tomographic angiography, and contrast enhanced magnetic resonance angiography.

ULTRASOUND

It was 39 years ago, in 1976, that the *British Medical Journal* announced that vascular labs were becoming familiar in their hospitals and that patients would be selected for reconstructive arterial surgery on the basis of routine ultrasound investigations alone.³ The initial work by Strandness et al in 1964 solidified duplex ultrasonography as the cornerstone of preoperative imaging.⁴

Always first in line after a thorough clinical evaluation, duplex ultrasonography utilizing both gray scale (B-mode) and color flow Doppler is a safe, inexpensive technique resulting in useful information. It is an important part of preoperative imaging in an endovascular program. A thorough, meticulous examination by an experienced operator is time consuming but beneficial. Information gathered can be used to diagnose a clinically significant stenosis. This is operator dependent, and multisegmental disease can make interpretation difficult.⁵ When reviewing an outside sonogram, carefully assess the information it provides and don't be afraid to correlate it with another imaging modality.

Experienced ultrasonographers can scan a lower extremity to identify hemodynamically significant plaque. Calcified plaque makes scanning difficult, if not almost impossible. What may mimic a severe stenosis may actually be a total occlusion at the time of angiography. Total occlusions, whether in the superficial femoral artery, the popliteal artery, or the tibials, can be identified, but distal reconstitution can be difficult to recognize, depending on collateral flow. Current complex critical limb ischemia cases require that the interventionalist know if the distal tibials are patent prior to angiography. In the past, tibial patency was difficult to ascertain, but Mustapha et al showed that the overall sensitivity of ultrasound in detecting tibial artery patency was calculated at 93%.⁶ Thirty years ago, Jager et al concluded that noninvasive mapping was as good as arteriography in defining the location and the extent of arterial involvement.⁷ For some centers, ultrasound is the only modality used prior to angiography. Future technological advancements will change ultrasound from a 2-dimensional into a 3-dimensional model, which will further enhance lower extremity imaging, and allow better assessments of the degree and extent of calcified stenotic lesions.⁸

COMPUTERIZED TOMOGRAPHIC ANGIOGRAPHY

Some of the first articles describing computerized tomographic angiography (CTA) appeared in the November 1992 issue of *Radiology*.^{9,10} Its current state, CTA is still noninvasive, requires higher volumes of contrast, has high doses of radiation that are being scrutinized, and can be difficult to reconstruct and interpret in

highly calcified vessels.⁵ Use of different viewing windows can assist in plaque burden assessments, allowing the physician to more accurately identify stenoses that were not seen with contrast bolus itself. I make it my routine to follow the source images through the artery of interest, looking for the pattern of calcium distribution and trying to identify the areas of severe stenosis or occlusion. Vessels with dense calcification can result in overestimation of stenosis.¹¹ Dual-energy CTA post-processing allows differentiation of iodine from calcium^{8,11} and is very promising. In certain situations where infrainguinal stents have been placed, CTA has shown superiority over magnetic resonance angiography (MRA) in the evaluation of restenosis.¹¹

MAGNETIC RESONANCE ANGIOGRAPHY

Magnetic resonance angiography (MRA) has evolved over the past 23 years. Operators once felt it would remain an investigational technique,¹² but currently, with its contrast-enhanced 3-dimensional technique, it has become an alternative to angiography in some instances. It can take advantage of the difference in signal properties between static tissue and flowing blood.¹¹

Magnetic resonance angiography can provide excellent 3-dimensional images, but it can overestimate the degree of stenosis.¹³ Contrast-enhanced MRA, performed appropriately, reduces venous contamination and can display distal tibial segments that cannot be detected by digital subtraction angiography (DSA).^{14,15} Long-segment CTOs of the tibials are difficult to visualize with DSA, but MRA can image blood flow at velocities as low as 2 cm/sec, establishing target vessels for revascularization and helping with planning.¹⁶ Remember to avoid gadolinium in patients with renal insufficiency, especially if their glomerular filtration rate is less than 30 mL/min/1.73m², given the risk of nephrogenic systemic fibrosis.

Most institutions offer the techniques discussed above. Each method has its advantages and disadvantages. As a specialist, one should be able to decide which method to choose initially and which imaging modality each institution performs best. I like to correlate the methods chosen and see if they agree with each other. This allows the opportunity to individualize an imaging protocol depending on the clinical presentation and the location of the ischemic lesion.

The TASC II guidelines² and the European Society of Cardiology recommend using MRA, CTA, or duplex to image the inflow and the distal vessels, taking into account cost, availability, and experience. The American Heart Association and American College of Cardiology support the use of CTA or MRA.

Most comparative studies use DSA as the gold standard. When CTA is compared to DSA, CTA performs well, showing 97% sensitivity and 94% specificity in the

femoropopliteal region. Tibial artery CTA shows 95% sensitivity and 91% specificity.¹¹ The higher performance 64-slice CT scanners increase these values to a sensitivity of 99% and specificity of 97%. Contrast-enhanced MRA can demonstrate sensitivities and specificities greater than 95% in these head-to-head studies.¹¹

CONCLUSION

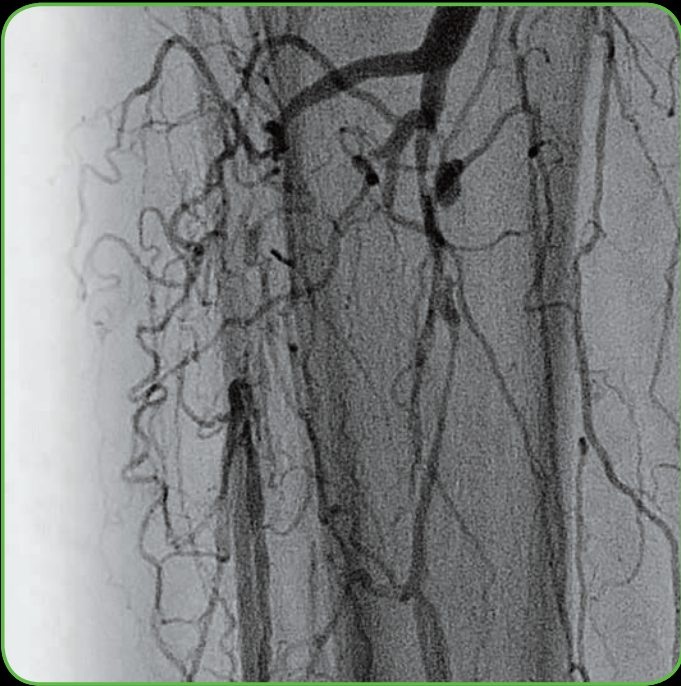
Endovascular specialists must consider all of the above before making a decision on which imaging modality will assist in planning decisions prior to selective angiography.¹⁷ There are instances where it could be helpful to use more than one modality. Imaging ahead of time will ensure you will be well prepared to take on the endovascular challenge of revascularization.

Disclosure: Dr. Pliagas discloses consultancy to and reimbursements from CSI as well as expert witness fees.

REFERENCES

- Scherthaner R, Fleischmann D, Stadler A, Scherthaner M, Lammer J, Loewe C. Value of MDCT angiography in developing treatment strategies for critical limb ischemia. *AJR Am J Roentgenol*. 2009;192(5):1416-1424.
- Norgren L, Hiatt WR, Dormandy JA, Nehler MR, Harris KA, Fowkes FG; TASC II Working Group. Inter-Society Consensus for the Management of Peripheral Arterial Disease (TASC II). *J Vasc Surg*. 2007;45 Suppl S:S5-S67.
- Measuring blood flow. *Br Med J*. 1976;2(6047):1279.
- Strandness DE Jr, Bell JW. An evaluation of the hemodynamic response of the claudicating extremity to exercise. *Surg Gynecol Obstet*. 1964;119:1237-1242.
- Pomposelli F. Arterial imaging in patients with lower extremity ischemia and diabetes. *J Vasc Surg*. 2010;52(3 Suppl):81S-91S.
- Mustapha JA, Saab F, Diaz-Sandoval L, Karenko B, McGoff T, Heaney C, Severson M. Comparison between angiographic and arterial duplex ultrasound assessment of tibial arteries in patients with peripheral arterial disease: on behalf of the Joint Endovascular and Non-Invasive Assessment of Limb Perfusion (JENALI) Group. *J Invasive Cardiol*. 2013;25(11):606-11.
- Jäger KA, Phillips DJ, Martin RL, et al. Noninvasive mapping of lower limb arterial lesions. *Ultrasound Med Biol*. 1985;11(3):515-521.
- Janvier MA, Merouche S, Allard L, Soulez G, Cloutier G. A 3-D ultrasound imaging robotic system to detect and quantify lower limb arterial stenoses: in vivo feasibility. *Ultrasound Med Biol*. 2014;40(1):232-243.
- Napel SI, Marks MP, Rubin GD, et al. CT angiography with spiral CT and maximum intensity projection. *Radiology*. 1992;185(2):607-610.
- Schwartz RB, Jones KM, Chernoff DM, et al. Common carotid artery bifurcation: evaluation with spiral CT. Work in progress. *Radiology*. 1992;185(2):513-519.
- Pollak AW, Norton PT, Kramer CM. Multimodality imaging of lower extremity peripheral arterial disease: current role and future directions. *Circ Cardiovasc Imaging*. 2012;5(6):797-807.
- Sueyoshi EI, Sakamoto I, Matsuoka Y, et al. Aortoiliac and lower extremity arteries: comparison of three-dimensional dynamic contrast-enhanced subtraction mr angiography and conventional angiography. *Radiology*. 1999;210(3):683-688.
- Fenchel SI, Wisianowsky C, Schams S, et al. Contrast-enhanced 3D MRA of the aortoiliac and infrainguinal arteries when conventional transfemoral arteriography is not feasible. *J Endovasc Ther*. 2002;9(4):511-519.
- Andreisek G, Pfammatter T, Goepfert K, et al. Peripheral arteries in diabetic patients: standard bolus-chase and time resolved MR angiography. *Radiology*. 2007;242(2):610-620.
- Lapeyre M, Koberer H, Desgranges P, Rahmouni A, Becquemin JP, Luciani A. Assessment of critical limb ischemia in patients with diabetes: comparison of MR angiography and digital subtraction angiography. *AJR Am J Roentgenol*. 2005;185(6):1641-1650.
- Zhu YQ, Wang J, Tan HQ, et al. Runoff detected by magnetic resonance angiography as an indicator for better recanalization outcomes in below-the-knee chronic total occlusions in diabetic patients. *J Endovasc Ther*. 2015;22(2):243-251.
- Chan D, Anderson ME, Dolmatch BL. Imaging evaluation of lower extremity infrainguinal disease: role of the noninvasive vascular laboratory, computed tomography angiography, and magnetic resonance angiography. *Tech Vasc Interv Radiol*. 2010;13(1):11-22.

THINK YOU'RE OUT OF OPTIONS WHEN ANTEGRADE FAILS?



Pre Treatment

Case Study

88 y/o female

Rutherford category 4 with a medial plantar ulcer and osteomyelitis

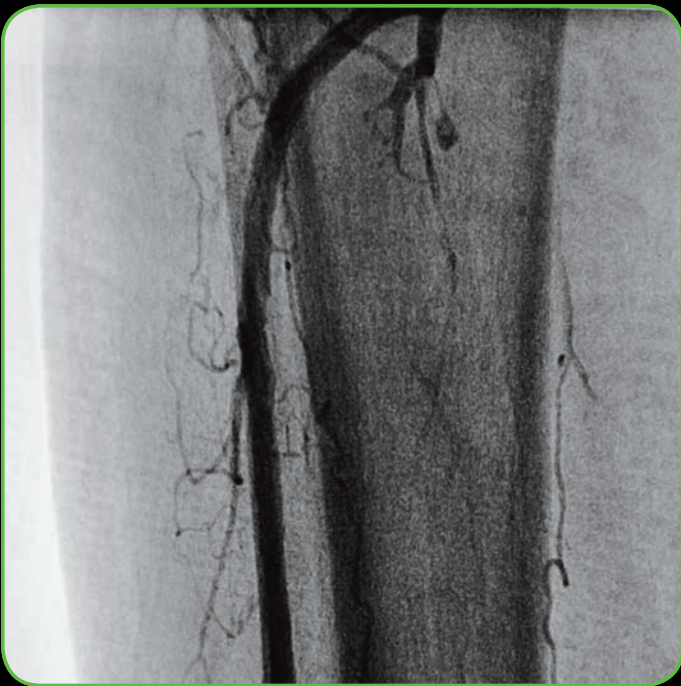
3 vessels treated from the AT

with one device: SFA, popliteal, and AT

≥ 75% stenosis

in each of the three vessels

Patient presented with lower extremity pain and was diagnosed with PAD. Past history of diabetes mellitus, renal insufficiency, hypertension and coronary artery disease. After multiple unsuccessful attempts to treat from femoral access, orbital atherectomy was performed with a 4 Fr tibiopedal retrograde approach.



Post OAS and PTA

Outcome*

< 5%

residual stenosis in all target lesions

< 1

day in hospital

0

bleeding complications

**Results may not be typical*



The CSI Orbital Atherectomy System is a percutaneous orbital atherectomy system indicated for use as therapy in patients with occlusive atherosclerotic disease in peripheral arteries and stenotic material from artificial arteriovenous dialysis fistulae. Contraindications for the system include use in coronary arteries, bypass grafts, stents, or where thrombus or dissections are present. Although the incidence of adverse events is rare, potential events that can occur with atherectomy include: pain, hypotension, CVA/TIA, death, dissection, perforation, distal embolization, thrombus formation, hematuria, abrupt or acute vessel closure, or arterial spasm.

Caution: Federal law (USA) restricts this device to sale by, or on the order of, a physician.

Case study courtesy of Sadeem Mahmood, M.D., FACC, South Arkansas Cardiology, PLLC Pine Bluff, AR. Case study results may vary. Dr. Mahmood is a paid consultant for Cardiovascular Systems, Inc.

©2015 Cardiovascular Systems, Inc. EN-2523 0815

Three Key Considerations in the Treatment of Critical Limb Ischemia

Tom Davis, MD, and James Torey, PA-C

From the St. John Hospital and Medical Center, Detroit, Michigan.



Tom Davis, MD

Critical limb ischemia (CLI) is defined as limb pain that occurs at rest, or impending limb loss that is caused by severe compromise of blood flow to the affected extremity.¹ Chronic ischemia can lead to critical changes that may involve trophic lesions or gangrene of the legs and is considered the end stage of peripheral arterial disease (PAD).^{2,3} These are classified as Rutherford Class IV, V, or VI. Critical limb ischemia frequently presents as multilevel and multivessel disease and presents challenges when considering the optimal strategy for treatment. When performing CLI percutaneous intervention, especially multilevel, the three things to keep in mind are determining the angiosome that is affected, maximizing the inflow and outflow, and understanding when the goal of therapy is reached.

ANGIOSOME DETERMINATION

First, in-line flow to the angiosome vessel is imperative for wound healing. The angiosome model for treatment takes into account a division of the body into three-dimensional vascular territories supplied by specific source arteries.⁴ Direct intervention to the affected angiosome shows a high rate of ulcer healing, especially in the absence of collateral circulation.⁵⁻⁷

Prior to starting the case we will be sure to map out the wound or ischemic area on the foot and know which vessel will be targeted (see figure). We also have a discussion with the patient's wound care specialist to ascertain if an amputation is being considered. For instance, if a transmetatarsal amputation

is a possibility, the plantar flap will need adequate perfusion and the calcaneal branches from the peroneal and the posterior tibial arteries will be the target. Secondary targets will be the communicating ("choke") vessels between the anterior tibial and peroneal artery and posterior tibial artery. Similar choke vessels exist between the peroneal and posterior tibial vessels.

MAXIMIZING INFLOW AND OUTFLOW

Second, inflow and outflow must be maximized. The idea that improving inflow will help improve outflow through collaterals may be feasible for patients who present with claudication but not for wound healing. In a suboptimal intervention, rest pain may be improved, but wound healing will not be achieved. Therefore, limb salvage does not equal vessel patency but adequate flow distal to the target lesion.

In my practice, I treat the inflow vessel first to allow better visualization of the outflow target vessel. If there is any embolization distally, this can be taken care of when dealing with the outflow. A significant advantage in this approach is that the vessels distal to the target lesion are frequently occluded rather than stenotic; therefore, the outflow occlusion can act as a surrogate filter. A notable exception to this strategy is when the iliac is involved and requires stenting. To avoid advancing the sheath through a freshly placed stent, I will angioplasty the iliac lesion to allow sheath passage if needed, fix every distal lesion next and then place the iliac stent last.

Once the inflow has been improved, I will take a more detailed view of the outflow. The outflow vessels are usually the tibials, which are frequently occlusive and lengthy. Having improved proximal flow often brings out hibernating vessels that were not seen on the initial angiograms such as collateral vessels and communicating ("choke") vessels, which can be important channels to navigate through to achieve successful wound healing.

Initial attempts at crossing typically involve using a central lumen-crossing device in order to reduce the risk of perforations, flow-limiting dissections, and hematomas. Perforations from wire crossings, which are more common with hydrophilic wires, can be difficult to treat and are sometimes unforgiving.

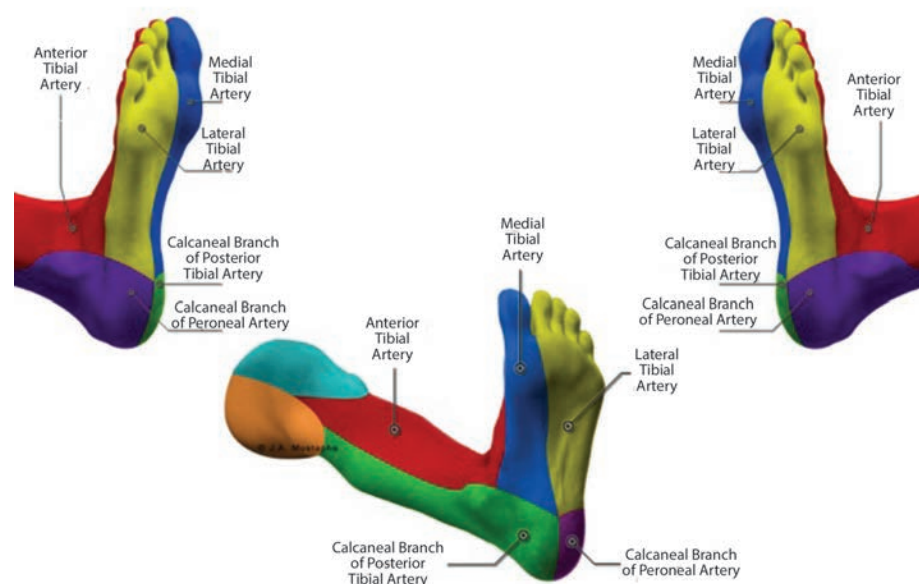


Figure. Angiosomes of the foot and ankle. Image courtesy J.A. Mustapha, MD.

Covered stents for the tibial vessels are not readily available and the only potential salvage in these situations may be prolonged balloon inflations or embolization techniques. Once I have crossed distally, I will typically bring down a support catheter, remove the wire, and inject into the distal space to confirm intraluminal access. It is not uncommon to find plantar or pedal stenosis that should also be treated to maximize outflow. When treating the outflow, the use of balloons and or atherectomy devices is the typical treatment algorithm. Stenting in the tibial vessels has been done for focal lesions, but there are no approved stents for the peripheral arteries below the knee to date. My go-to strategy for the distal reference is rotational or orbital atherectomy followed by adjunctive balloon angioplasty.

KNOW WHEN THE GOAL IS ACHIEVED

Lastly, due to the differences in the caliber when treating multiple infrapopliteal vessels, it is almost impossible to use the same treatment modality for every vessel. Cost per case can skyrocket if using multiple atherectomy devices for treatment of the various vessels. Therefore, it is important to know that durability of the procedure is not as important as short-term success of adequate blood flow to limb salvage. Restenosis should be low on the list of factors that play into the choice of device to open the occlusion. Getting a good initial result should be the goal. With this in mind, I will use the simplest device that will get a good outcome. Peripheral angioplasty, with long-lasting balloon inflations, have shown a high rate of acute success (95%), acceptable 5-year limb salvage rates (88%) and acceptable repeat intervention rates (12.7%).⁸ Focal stenoses will usually respond to balloon angioplasty, whereas long heavily calcified vessels or restenotic vessels will respond

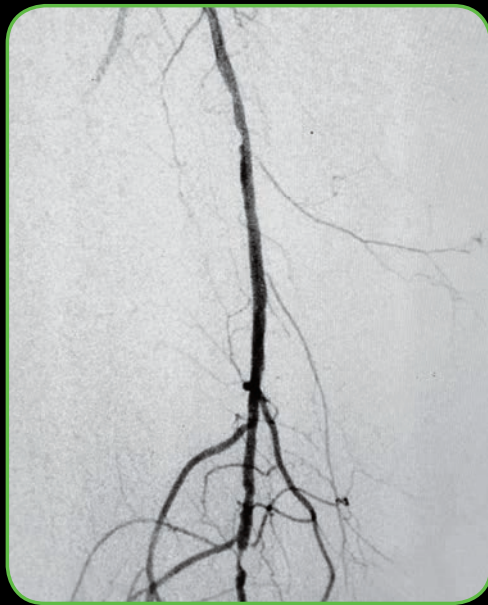poorly. In these cases, I will use atherectomy or stenting as first-line treatment. Even with the various and complex morphologies that exist, there is usually a treatment strategy that will be a good first-line therapy.

Disclosure: Dr. Davis reports honoraria, advisory board membership, and travel expense reimbursement as well as stock ownership with Avinger. James Torey reports no related disclosures.

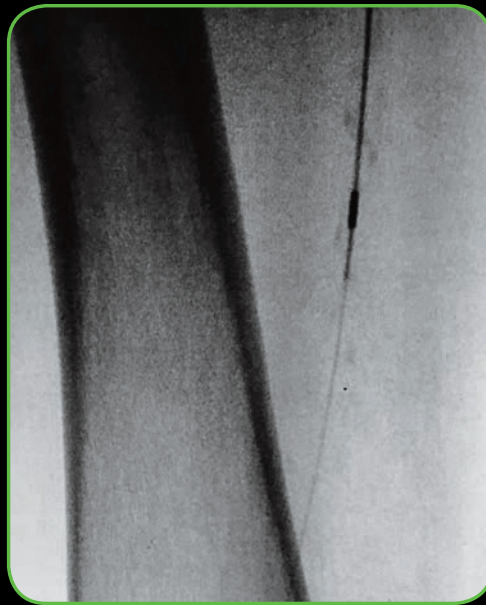REFERENCES

1. Hirsch AT, Haskal ZJ, Hertzler NR, et al. ACC/AHA 2005 Practice guidelines for the management of patients with peripheral arterial disease (lower extremity, renal, mesenteric, and abdominal aortic): Executive summary—A collaborative report from the American Association for Vascular Surgery/Society for Vascular Surgery, Society for Cardiovascular Angiography and Interventions, Society for Vascular Medicine and Biology, Society of Interventional Radiology, and the ACC/AHA Task Force on Practice Guidelines (Writing committee to develop guidelines for the management of patients with peripheral arterial disease). *Circulation*. 2006;113(11):e463-654.
2. Serrano Hernando FJ, Martín Conejero A. Peripheral artery disease: pathophysiology, diagnosis and treatment [article in Spanish]. *Rev Esp Cardiol*. 2007;60(9):969-982.
3. Norgren L1, Hiatt WR, Dormandy JA, et al. Inter-society consensus for the management of peripheral arterial disease (TASC II). *Eur J Vasc Endovasc Surg*. 2007;33 Suppl 1:S1-75.
4. Antonopoulos AG, Thomopoulos M, Trikas A. The role of the angiosome model in percutaneous intravascular and surgical reperfusion treatment of peripheral artery disease of the lower limbs. *Hellenic J Cardiol*. 2014;55(1):52-57.
5. Attinger CE, Evans KK, Mesbahi A. Angiosomes of the foot and angiosome-dependent healing. In: A Sidway, ed. *Diabetic foot, lower extremity arterial disease and limb salvage*. Philadelphia: Lippincott Williams & Wilkins; 2006: 341-350.
6. Varela C, Acín F, de Haro J, Bleda S, Esparza L, March JR. The role of foot collateral vessels on ulcer healing and limb salvage after successful endovascular and surgical distal procedures according to the angiosome model. *Vasc Endovascular Surg*. 2010;44(8):654-660.
7. Iida O, Nanto S, Uematsu M, et al. Importance of the angiosome concept for endovascular therapy in patients with critical limb ischemia. *Catheter Cardiovasc Interv*. 2010;75(6):830-836.
8. Faglia E1, Dalla Paola L, Clerici G, et al. Peripheral angioplasty as the first-choice revascularization procedure in diabetic patients with critical limb ischemia: prospective study of 993 consecutive patients hospitalized and followed between 1999 and 2003. *Eur J Vasc Endovasc Surg*. 2005;29(6):620-627.

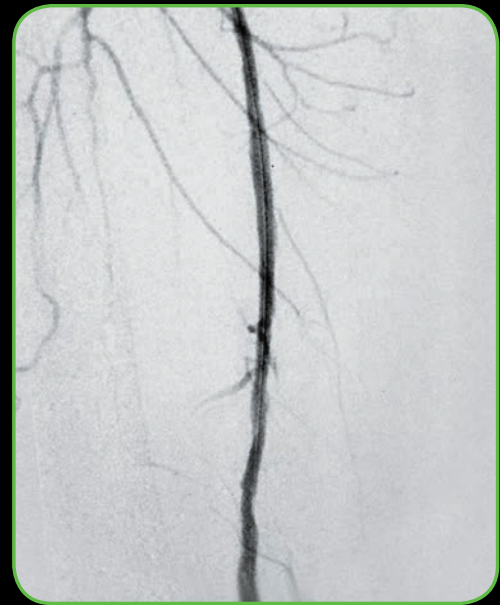THINK YOU NEED TO INCREASE SHEATH SIZE?



Pre Treatment



OAS Crown



Post OAS and PTA

Case Study

49 y/o female

Rutherford category 4

5th toe

non-healing wound,
de novo treatment

2 lesions

SFA, 90% and 60% stenosed

ATK procedure with femoral access used orbital atherectomy with an antegrade approach through a 5 Fr sheath with a 4 Fr 1.25 mm Solid Crown to treat both distal and proximal SFA. Use of smaller profile sheath sizes may be associated with reduced risk of bleeding complications.¹

Outcome*

30 minutes

total procedure time

< 10%

residual stenosis

0

bleeding complications

**Results may not be typical*



The CSI Orbital Atherectomy System is a percutaneous orbital atherectomy system indicated for use as therapy in patients with occlusive atherosclerotic disease in peripheral arteries and stenotic material from artificial arteriovenous dialysis fistulae. Contraindications for the system include use in coronary arteries, bypass grafts, stents, or where thrombus or dissections are present. Although the incidence of adverse events is rare, potential events that can occur with atherectomy include: pain, hypotension, CVA/TIA, death, dissection, perforation, distal embolization, thrombus formation, hematuria, abrupt or acute vessel closure, or arterial spasm.

Caution: Federal law (USA) restricts this device to sale by, or on the order of, a physician.

1. Ortiz B et al, Access Site Complications After Peripheral Vascular Interventions, Circ Cardiovasc Interv. 2014;7:821-828.

Case study courtesy of Mazin I. Foteh, M.D., Vascular and Endovascular Specialist, Cardiothoracic and Vascular Surgeons, Austin, Texas. Case study results may vary. Dr. Foteh is a paid consultant for Cardiovascular Systems, Inc.

©2015 Cardiovascular Systems, Inc. EN-2523 0815

CSI | **CARDIOVASCULAR
SYSTEMS, INC.**

Does Endovascular Revascularization Ruin Surgical Options Above and Below the Knee?

Vinayak Subramanian, BS¹; George L. Adams, MD, MHS²

From ¹Department of Biomedical Engineering, North Carolina State University, Raleigh, North Carolina, and ²Rex Hospital, University of North Carolina Health System, Raleigh, North Carolina.



George L. Adams, MD, MHS

The widespread epidemics of diabetes, kidney disease, and obesity have all led to an increase in the incidence of vascular disease. Peripheral arterial disease (PAD) is one of the most prevalent forms of vascular disease and affects 8 million to 12 million Americans and an estimated 202 million people worldwide.^{1,2} Those affected with PAD present with a range of different symptoms, from asymptomatic to rest pain and non-healing wounds. The latter is a characteristic of critical limb ischemia (CLI), the worst-case scenario. Patients with CLI are often faced with the grim possibility of limb amputation due to nonhealing wounds leading to gangrene and infection. Patients with PAD who undergo an amputation have increased morbidity and mortality. The 5-year mortality associated with amputation due to PAD approaches 50%.³ Revascularization of these vessels to support wound healing is one of the last resorts available to patients facing the possibility of amputation.

The goal of revascularization is to improve in-line pressure to distal vasculature, improving perfusion of ischemic tissue and enhancing wound-healing efforts. Both surgical and endovascular revascularization of peripheral vessels can be employed to reach this goal. In recent years, endovascular revascularization has overtaken surgical procedures as the preferred treatment option.⁴ Endovascular procedures are

minimally invasive and have fewer associated complications when compared to surgery. Furthermore, these catheter-based procedures can be employed on patients who are poor surgical candidates, thereby expanding therapeutic options to a previously underserved population. Advances in the development of novel interventional tools and treatment techniques have allowed interventionalists to treat a wider and more complex variety of cases. Keeping this in mind, an interventionalist must treat in a manner to leave the patients with surgical options if endovascular therapy fails.

AREAS OF CONCERN

Access

Cases of CLI often present with multilevel disease, both above and below the knee. An estimated 67% of CLI cases present with both femoropopliteal and infrapopliteal disease.⁵ Multiple access modalities, including contralateral retrograde (common femoral), antegrade (common femoral, popliteal), and retrograde (common femoral, superficial femoral, popliteal, tibial, and digital) are utilized to treat arterial occlusions. Care must be taken with each access modality to preserve bailout surgical revascularization options. With each access, the operator runs the risk of dissection, arteriovenous fistula formation, pseudoaneurysm, and bleeding complications. Each of these access risks can eliminate the opportunity for bail-out surgical revascularization.

Understanding the anatomy, angiographic techniques, and external ultrasound guidance for accurate access can reduce these complications. Additionally, bleeding complications are directly correlated to larger sheath sizes; therefore, using low-profile devices and smaller sheaths is recommended. Retrograde access through smaller vessels should be reserved as a second line of attack for traditional femoral access, because accessing smaller vessels may lead to similar complications as well as thrombosis.⁶ For example, if a retrograde access is attempted and a complication such as thrombosis occurs distal to a bail-out surgical target, the patient may lose the option of surgical bypass.

Treatment

Recently, there has been a proliferation of novel endovascular tools for

treating peripheral arterial disease. Each of these tools has inherent risks that may complicate future surgical options. A skilled interventionalist must have the foresight to predict potential complications while treating lesions and put safeguards in place to preserve the option of surgical bail-out. Understanding how various treatment tools can be deployed to best treat a variety of plaque morphologies is critical for successful revascularization. The use of intravascular ultrasound (IVUS) can assist in determining the appropriate treatment strategy for each case. For example, if plain old balloon angioplasty (POBA) is used on a heavily calcified lesion, the propagation of uncontrolled pressure vectors can lead to spiral dissections that require bail-out stenting. Future surgical revascularization can be adversely affected if the stents are placed near potential bypass targets. Early assessment of the plaque morphology would prompt the clinician to modify the plaque with atherectomy before PTA to reduce the risk of dissection and ultimately preserve future surgical bypass targets.

In addition to dissection, distal embolization can reduce the odds of successful surgical revascularization. Embolization is a risk when using aggressive techniques such as atherectomy and when treating soft-fatty plaques using traditional PTA and stenting techniques. Distal embolization is a significant cause for concern when treating complex multilevel disease and is encountered in most CLI cases. These emboli compromise distal flow and can reduce the efficacy of endovascular and surgical procedures. The use of embolic protection devices is recommended when treating the complex disease characteristic of CLI. Use of these devices can preserve surgical options.

HYBRID APPROACH

There is much debate about whether endovascular or surgical therapy is optimal for treating multilevel PAD. However, a hybrid approach utilizing both treatment paradigms may be most beneficial to patients. Advances in the development of endovascular devices have broadened the scope of treatment for peripheral vascular interventions, but some types of lesions are best treated with surgical endarterectomy or bypass. For example, a patient with CLI

presenting with a long diseased lesion of the SFA is best treated using a surgical approach. However, these patients may also have significant tibial, and popliteal disease.

Davies et al previously showed that patency of the inflow is dependent on the patency of the outflow and vice versa. Endovascular revascularization of the outflow before surgical treatment of the inflow can improve the patency of the femoropopliteal bypass, which allows for improved patient outcomes.⁷

CONCLUSION

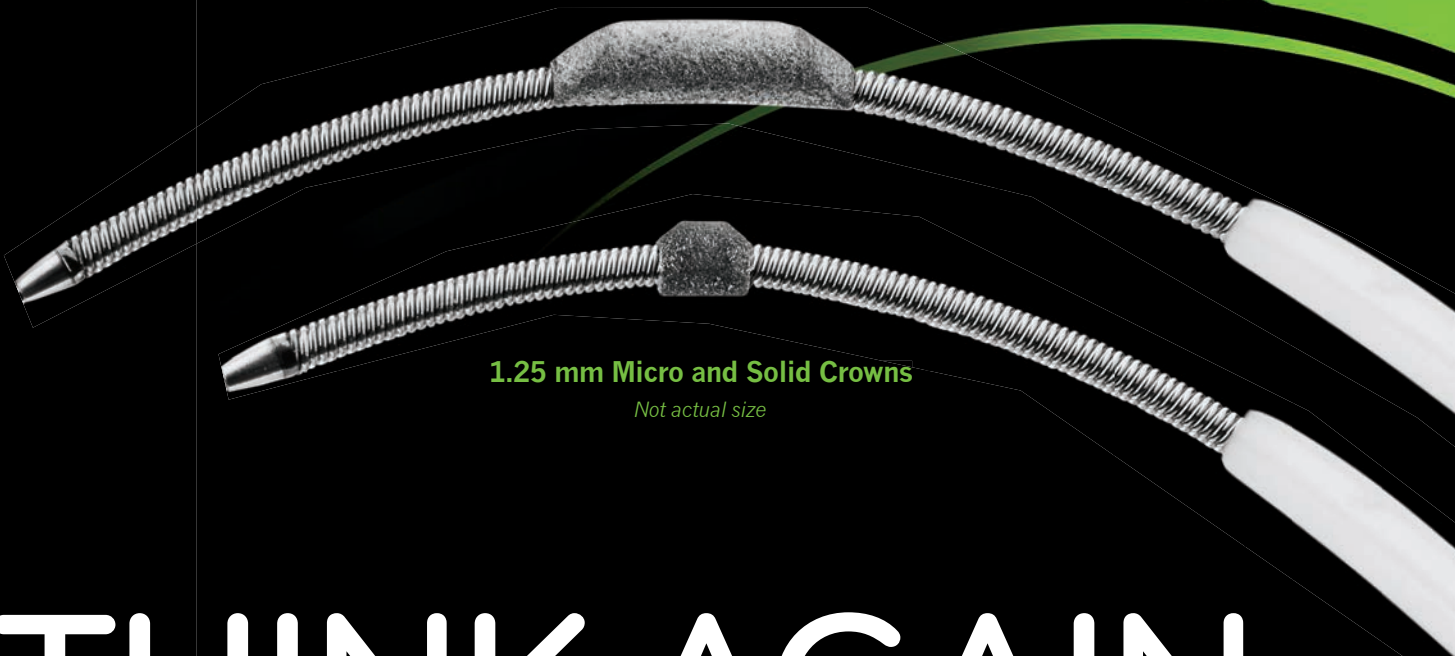
Treating complex PAD cases is predicated on the skill of the clinician. An interventionalist must treat with an eye toward the future and understand how present treatment can affect options available to the patient in the future. Planning ahead for potential complications associated with endovascular access and treatment will allow the clinician to preserve the chances for surgical options in the future.

Similarly, complications of vascular surgery can adversely affect future endovascular treatment. Development of excess scar tissue after endarterectomy or tying off arteries after bypass can eliminate the possibility of future endovascular procedures, which may be needed if surgery alone isn't successful in improving the patency. While it is unclear if one is better than the other, utilizing a hybrid approach of both endovascular therapy and surgery to determine the best course of treatment that is optimal for the patient is essential as we begin to see a growth in the number of patients presenting with complex PAD.

Disclosure: The authors report no disclosures related to the content herein.

REFERENCES

1. Roger VL, Go AS, Lloyd-Jones DM, et al; American Heart Association Statistics Committee and Stroke Statistics Subcommittee. Heart disease and stroke statistics --2012 update: a report from the American Heart Association. *Circulation*. 2012;125(1):e2-e220.
2. Fowkes FG, Rudan D, Rudan I, et al. Comparison of global estimates of prevalence and risk factors for peripheral artery disease in 2000 and 2010: a systematic review and analysis. *Lancet*. 2013;382(9901):1329-1340.
3. Varu VN, Hogg ME, Kibbe MR. Critical limb ischemia. *J Vasc Surg*. 2010;51(1):230-241.
4. Goodney PR, Beck AW, Nagle J, Welch HG, Zwolak RM. National trends in lower extremity bypass surgery, endovascular interventions, and major amputations. *J Vasc Surg*. 2009;50(1):54-60.
5. Gray BH, Diaz-Sandoval LJ, Dieter RS, Jaff MR, White CJ; Peripheral Vascular Disease Committee for the Society for Cardiovascular Angiography and Interventions. (2014). SCAI expert consensus statement for infrapopliteal arterial intervention appropriate use. *Catheter Cardiovasc Interv*. 2014;84(4):539-545.
6. Ortiz D, Jahangir A, Singh M, Allaqaband S, Bajwa TK, Mewissen MW. Access Site Complications After Peripheral Vascular Interventions Incidence, Predictors, and Outcomes. *Circ Cardiovasc Interv*. 2014 Dec;7(6):821-828.
7. Davies MG, Saad WE, Peden EK, Mohiuddin IT, Naoum JJ, Lumsden AB. Impact of runoff on superficial femoral artery endoluminal interventions for rest pain and tissue loss. *J Vasc Surg*. 2008;48(3):619-625.



THINK AGAIN.

The 4 Fr Diamondback 360® Peripheral Orbital Atherectomy System enables treatment via either femoral or tibiopedal approaches.

Expand your PAD treatment options with our ultra-low profile devices.

Think this is interesting?

Visit CSI360.com/thinkagain to find out more.



Treat cases once thought untreatable.

DIAMONDBACK 360®
PERIPHERAL ORBITAL ATHERECTOMY SYSTEM

877-CSI-0360 // WWW.CSI360.COM

The CSI Orbital Atherectomy System is a percutaneous orbital atherectomy system indicated for use as therapy in patients with occlusive atherosclerotic disease in peripheral arteries and stenotic material from artificial arteriovenous dialysis fistulae. Contraindications for the system include use in coronary arteries, bypass grafts, stents, or where thrombus or dissections are present. Although the incidence of adverse events is rare, potential events that can occur with atherectomy include: pain, hypotension, CVA/TIA, death, dissection, perforation, distal embolization, thrombus formation, hematuria, abrupt or acute vessel closure, or arterial spasm.

Caution: Federal law (USA) restricts this device to sale by, or on the order of, a physician.

CSI, Diamondback and Diamondback 360 are registered trademarks of Cardiovascular Systems, Inc.
©2015 Cardiovascular Systems, Inc. EN-2523 0815

CSI | **CARDIOVASCULAR
SYSTEMS, INC.**

Drug-Coated Balloon Angioplasty for the Treatment of Calcified Tibial Vessels

J.A. Mustapha, MD; Larry J. Diaz-Sandoval, MD; Fadi Saab, MD
From Metro Health Hospital, Wyoming, Michigan.



Larry J. Diaz-Sandoval, MD

One-year mortality and major amputation rates for critical limb ischemia (CLI) range from 20% to 50%.¹⁻³ The natural history of advanced peripheral artery disease (PAD) is characterized by progression and shift to CLI, and therefore a parallel increase in its incidence is expected as the patient population continues to age. Efforts to identify and treat these patients at an earlier point (the “pre-CLI” stage) should be undertaken: when patients transition from PAD to CLI, the therapeutic algorithm should transition accordingly and be made urgent rather than elective.

Evolutions in technology, techniques, and approaches are currently disrupting the therapeutic paradigm in CLI. The surgical approach used to represent the “standard of care” for infrapopliteal lesions classified as TASC D (the vast majority of patients with CLI). However, coexisting comorbidities, lack of adequate outflow vessels or “targets,” and lack of suitable conduits for bypass commonly limit the role of vascular surgery. Because of this, endovascular revascularization has become the default therapeutic option, as successful interventions can be achieved in most cases, even in tibial arteries with complex disease. Arterial patency after percutaneous transluminal angioplasty (PTA) tends to be short lived due to elastic recoil, neointimal hyperplasia, and restenosis with primary patency rates of 48% to 81% at 1 year and 40% to 78% at 2 years,⁴ although limb salvage rates at 1 year have been deemed equivalent to bypass surgery in a recent meta-analysis.⁵ Attempts at improving patency rates (and hence long-term outcomes), have clearly been a challenge, as the extent of the disease (severity, length, and calcification) among CLI patients is far beyond that seen in patients with claudication. In the femoropopliteal segment, the arteries are exposed to unique biophysical forces that have compromised the intended improvement supposed to be gained by the use of stents, while below the knee, their use is limited due to the length of the lesions, the vessel diameter, and the superficial location of the tibial arteries.

DCBs IN THE LITERATURE

Recent studies have provided strong evidence to support the use of drug-coated balloons (DCBs) to significantly improve the sustainability of positive outcomes achieved with endovascular treatments. Ideal DCBs should enable both the transportation of the desirable drug dose to the treatment site as well as the drug’s immediate release into the vessel wall. Successful drug-assisted angioplasty depends on the harmonious and synergistic action of both the drug (paclitaxel, a cytotoxic agent that stops the cell cycle in the M phase of the mitotic cycle, with hydrophobic-lipophilic properties that facilitate its cellular uptake and deliverability following a single dose with maintained long-term results and limited toxicity) and the coating technology, which enables drug delivery to the target lesion with the least amount lost through the systemic circulation, while facilitating rapid and uniform drug release.

DCBs allow for the treatment of segments where stents could “jail” other vessel branches and provide the potentially perfect scenario of adequate treatment without leaving any metal behind. However, from a pathologic point of view, tibial arterial disease characteristically affects the media and is associated with a very high prevalence of calcification that could theoretically affect the diffusion of the drug into the media and adventitia. These pathologic premises have recently raised controversies regarding the efficacy of DCBs in tibial arteries. After successful single-center experiences,^{6,7} the most recent multicenter, randomized study comparing DCB to plain old balloons in the tibial vessels in patients with CLI failed to show improvement, and actually showed a trend toward increased amputations.⁸ Questions have arisen as to why this study failed to show benefit. Several theories have been postulated; however, no one has discussed whether or not there was proper determination of the size of the vessels and of the DCBs utilized. Despite the fact that there was no core lab adjudication of vessel size, the average reference vessel diameter in patients treated with DCB in DEBATE-BTK was 2.91 mm, while in IN.PACT DEEP it was 2.46 mm, which indirectly translates in the usage of DCBs that were at least 0.5 mm larger in DEBATE-BTK. The potential implications of this observation are that undersizing of balloons leads to lack of contact between the DCB and the arterial wall (Figure), which in turn results in the following:

- 1) Failure to deliver the antiproliferative drug to the vessel wall;
- 2) Loss of acute luminal gain; and
- 3) Downstream migrations of the drug/excipient, into the wound’s capillary beds (which act as drug “reservoirs” and foster wound nonhealing secondary to the accumulation of antiproliferative drugs that inhibit cell regeneration), potentially leading to increased adverse events.

The sizing issue has also partially been addressed in studies using intravascular ultrasound such as CALCIUM360,⁹ which showed that tibial arteries normally range in size from 2.5 mm distally, to 3.0 mm mid, and 3.5 mm proximally (in contrast to the average sizes reported in the two studies previously cited). These findings have also been confirmed by histopathologic studies. Kashyap et al compared the angiographic vs histologic size of the popliteal and tibial arteries from patients with CLI who ultimately underwent amputation, and determined that angiography (considered the “gold standard”) severely underestimated both the extent of atherosclerosis (even in “normal appearing” segments), and the size of the popliteal and tibial vessels.¹⁰

More recently, the use of extravascular ultrasound (EVUS) performed at the time of peripheral interventions has allowed accurate sizing of balloons and DCBs by matching them to the lesions and arterial segments being treated, increasing the contact between the balloon surface and the arterial wall.¹¹ Taking this simple extra step will likely lead to higher drug transfer and theoretically should lead to improved acute results and potentially

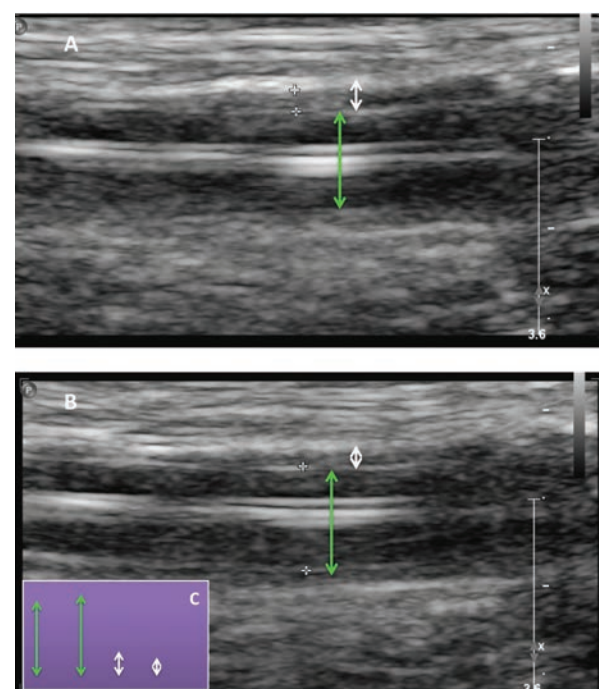


Figure 1. Proper 1:1 balloon sizing in the infrapopliteal vessels for optimization of drug delivery to the vessel wall during the utilization of DCB. Clearly defined inflated balloon in the popliteal. The green arrow shows the circumferential diameter of the balloon. The white arrow shows the large area not being accurately or properly treated due to undersizing of the balloon (A). The problem is fixed by using a proper 1:1 balloon based on the measurement (B). Real-time difference in balloon sizing (B, C). The left green arrow represent a 5.0-mm diameter balloon. Size was decided based on angiographic visual observation of the vessel angiogram. The right green arrow represents the 6.0-mm diameter balloon. The size was determined based on the direct measurement of the vessel diameter with extravascular ultrasound (EVUS). The left white double head arrow shows the significant amount of mismatch and uninterrupted plaque area between the undersized balloon and the vessel wall. The right white arrow shows the significant reduction in the plaque area after the balloon size was increased to match the 1:1 sizing of the balloon to vessel lumen ratio by EVUS.

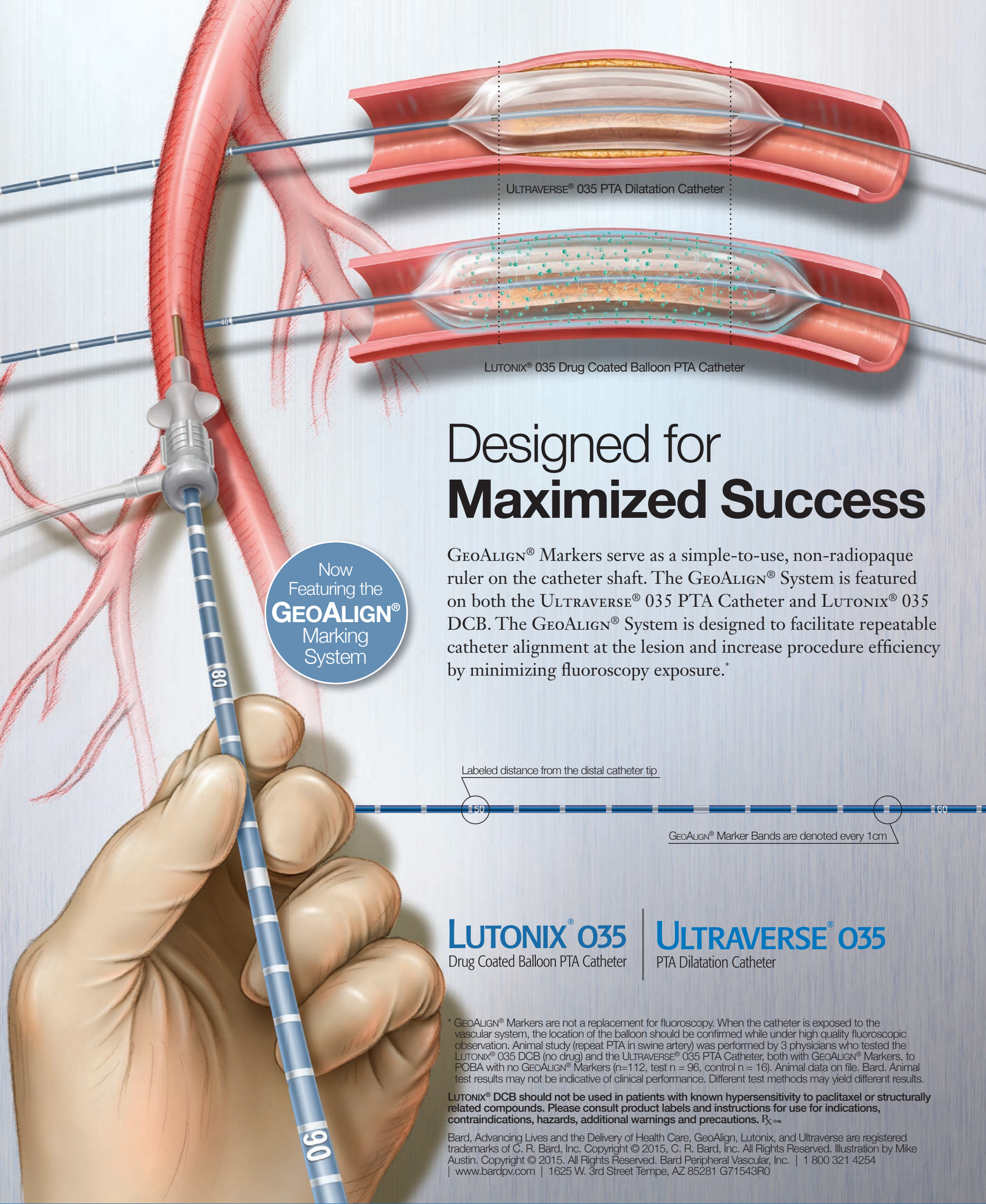
long-term outcomes. An artery with sustained patency is critical for tissue healing; therefore, maximizing the odds for a positive, reliable, and durable result should be attempted during peripheral vascular interventions in CLI.

This analysis offers a window into at least one of the elements that may account for the negative results of IN.PACT DEEP. While we do not expect to prove that sizing may be the only reason for these results, we do believe that this venue will provide us with a better understanding of the limitations of this technology and, more importantly, with a potentially simple way to overcome this hurdle.

CONCLUSION

Due to the complexity of the lesions seen in patients with CLI, (long, irregularly shaped, moderately to severely calcified stenoses and occlusions), DCBs represent an attractive and unique technology that can potentially achieve excellent, durable results. We believe that peripheral vascular interventions (PVI) using DCBs should be performed differently than conventional balloon angioplasty, with a clear understanding of the methodology to be used, the importance of adequate sizing, and avoidance of geographic miss. The drug-coated balloon cannot and should not be regarded as the “newest balloon,” as it is an entirely new device and its proper utilization

Continued on page 12



ULTRAVERSE® 035 PTA Dilatation Catheter

LUTONIX® 035 Drug Coated Balloon PTA Catheter

Now
Featuring the
GEOALIGN®
Marking
System

Designed for Maximized Success

GEOALIGN® Markers serve as a simple-to-use, non-radiopaque ruler on the catheter shaft. The GEOALIGN® System is featured on both the ULTRAVERSE® 035 PTA Catheter and LUTONIX® 035 DCB. The GEOALIGN® System is designed to facilitate repeatable catheter alignment at the lesion and increase procedure efficiency by minimizing fluoroscopy exposure.*

Labeled distance from the distal catheter tip

150

160

GEOALIGN® Marker Bands are denoted every 1cm

LUTONIX® 035
Drug Coated Balloon PTA Catheter

ULTRAVERSE® 035
PTA Dilatation Catheter

* GEOALIGN® Markers are not a replacement for fluoroscopy. When the catheter is exposed to the vascular system, the location of the balloon should be confirmed while under high quality fluoroscopic observation. Animal study (repeat PTA in swine artery) was performed by 3 physicians who tested the LUTONIX® 035 DCB (no drug) and the ULTRAVERSE® 035 PTA Catheter, both with GEOALIGN® Markers, to POBA with no GEOALIGN® Markers (n=112, test n = 96, control n = 16). Animal data on file. Bard. Animal test results may not be indicative of clinical performance. Different test methods may yield different results.

LUTONIX® DCB should not be used in patients with known hypersensitivity to paclitaxel or structurally related compounds. Please consult product labels and instructions for use for indications, contraindications, hazards, additional warnings and precautions. Rx only

Bard, Advancing Lives and the Delivery of Health Care, GeoAlign, Lutonix, and Ultraverse are registered trademarks of C. R. Bard, Inc. Copyright © 2015, C. R. Bard, Inc. All Rights Reserved. Illustration by Mike Austin. Copyright © 2015. All Rights Reserved. Bard Peripheral Vascular, Inc. | 1 800 321 4254 | www.bardpv.com | 1625 W. 3rd Street Tempe, AZ 85281 G71543R0

DCB for Tibial Vessels

Continued from page 10

requires the use of a specific technique that differs from that of plain PTA. As data on DCBs continue to be gathered and evolve and their use continues to increase, optimistic caution should be exercised. In the infrapopliteal segment, questions remain. Postulated answers include the need for further optimization of drug-eluting coatings; reduction (or elimination) of the downstream drug loss during balloon insertion; as well as increased drug penetration and persistence in the vessel wall after balloon inflation.

In our view, removal of the calcium barrier prior to treatment with DCB, followed by precise and adequate sizing of the DCBs in the tibiopedal vessels is likely to improve the outcomes observed until this point in CLI patients by maximizing drug transfer to the vessel wall and minimizing downstream loss.

As we move forward, gathering data in an attempt to solve the mystery of this era and enroll patients in studies of infrapopliteal use of DCBs, it is of paramount

importance to keep in mind that each combination of balloon, and drug/excipient, represents a unique device and that there is no “class effect.”

More importantly, it does appear that we may be in the midst of a “blast from the past,” where proper angioplasty techniques, such as correct sizing, slow inflation to decrease strain, prolonged inflation to allow for acute remodeling, low pressure to decrease barotrauma, and slow deflation to decrease barotrauma and avoid “Venturi” effect with resulting detachment of drug from the wall back into the lumen, are back in the spotlight. This reminds us of the words of John Hartford: “The whole universe is based on rhythms. Everything happens in circles, spirals.” Everything comes back to its point of origin, and here we are again...

REFERENCES

1. Bosiers M, Scheinert D, Peeters P, et al. Randomized comparison of everolimus-eluting versus bare metal stents in patients with critical limb ischemia and infrapopliteal arterial occlusive disease. The DESTINY Study. *J Vasc Surg.* 2012;55(2):390-398.
2. Balzer JO, Zeller T, Rastan A, et al. Percutaneous interventions below the knee in patients with critical limb ischemia using drug eluting stents. *J Cardiovasc Surg.* 2010;51(2):183-191.
3. Siablis D, Karnabatidis D, Katsanos K, Diamantopoulos A, Christeas N, Kagadis GC. Infrapopliteal application of Paclitaxel-eluting stents for critical

limb ischemia: Midterm angiographic and clinical results. *J Vasc Interv Radiol.* 2007;18(11):1351-1361.

4. Siablis D, Kraniotis P, Karnabatidis D, Kagadis GC, Katsanos K, Tsolakis J. Sirolimus-eluting versus bare stents for bailout after suboptimal infrapopliteal angioplasty for critical limb ischemia: 6-month angiographic results from a nonrandomized prospective single-center study. *J Endovasc Ther.* 2005;12(6):685-695.
5. Romiti M, Albers M, Brochado-Neto FC, Durazzo AE, Pereira CA, De Luccia N. Meta-analysis of infrapopliteal angioplasty for chronic critical limb ischemia. *J Vasc Surg.* 2008;47(5):975-981.
6. Schmidt A, Piorkowski M, Werner M, et al. First experience with drug-eluting balloons in infrapopliteal arteries. *J Am Coll Cardiol.* 2011;58(11):1105-1109.
7. Liistro F, Porto I, Angioli P, et al. Drug-eluting balloon in peripheral intervention for below the knee angioplasty evaluation (DEBATE-BTK): a randomized trial in diabetic patients with critical limb ischemia. *Circulation.* 2013;128(6):615-621.
8. Zeller T, Baumgartner I, Scheinert D, et al. Drug-eluting balloon versus standard balloon angioplasty for infrapopliteal arterial revascularization in critical limb ischemia: 12-month results from the IN.PACT DEEP randomized trial. *J Am Coll Cardiol.* 2014;64(15):1568-1576.
9. Shamas NW, Lam R, Mustapha J, et al. Comparison of orbital atherectomy plus balloon angioplasty vs. balloon angioplasty alone in patients with critical limb ischemia: results of the CALCIUM 360 randomized pilot trial. *J Endovasc Ther.* 2012;19(4):480-488.
10. Kashyap VS, Pavkov ML, Bishop PD, et al. Angiography underestimates peripheral atherosclerosis: lumenography revisited. *J Endovasc Ther.* 2008;15(1):117-125.
11. Mustapha JA, Diaz-Sandoval LJ, Saab F. ExtraVascular UltraSound Imaging of Infrapopliteal Vessels and CLI Devices. In: JA Mustapha, ed. *Critical Limb Ischemia: CLI Diagnostics and Interventions*. Malvern, PA: HMP Communications LLC. 2015;101-118.

Tibial Interventions

Continued from page 3

This technology uses an eccentrically weighted diamond-coated crown rotating at high speeds to centrifugally disrupt vessel calcium. Thus, subsequent balloon inflation can be performed at lower pressures,⁵ and more importantly, balloons can be inflated uniformly and without the production of a “sausage-link” configuration. This uniform inflation results in an even vessel injury along the treated vessel length that is less predisposed to focal or asymmetric recoil, major dissection, and intimal hyperplasia. Early data from 50 patients in the Calcium 360 trial, randomized to PTA alone or PTA following OA found target lesion revascularization rates of 20% and 7%, respectively.⁶ In all cases, the best outcomes of OA (reduction in angiographic adverse events) are achieved with low spin rates, fewer passes, and slower advancement of the rotating crown during treatment.⁷ While the normal mechanism of PTA is to produce focal intimal and medial disruption, flow-limiting dissections or significant acute recoil may occur, particularly with eccentrically calcified lesions. Several studies have shown that coronary drug-coated balloons are remarkably effective in providing scaffolding and a biological inhibition of restenosis for short tibial lesions.⁸ A review of tibial DES data found 24-month primary patency of 73% and limb salvage of 86% in 240 patients with tibial stenosis under 3 cm in length.⁹ This suggests that longer DES designed specifically for tibial use could impact long-term patency.

ANGIOGRAPHIC ASSESSMENT

There are 6 major vascular trunks, or angiosomes, to the foot, with each perfusing a distinct region of the foot. A review of angiosome-directed revascularization

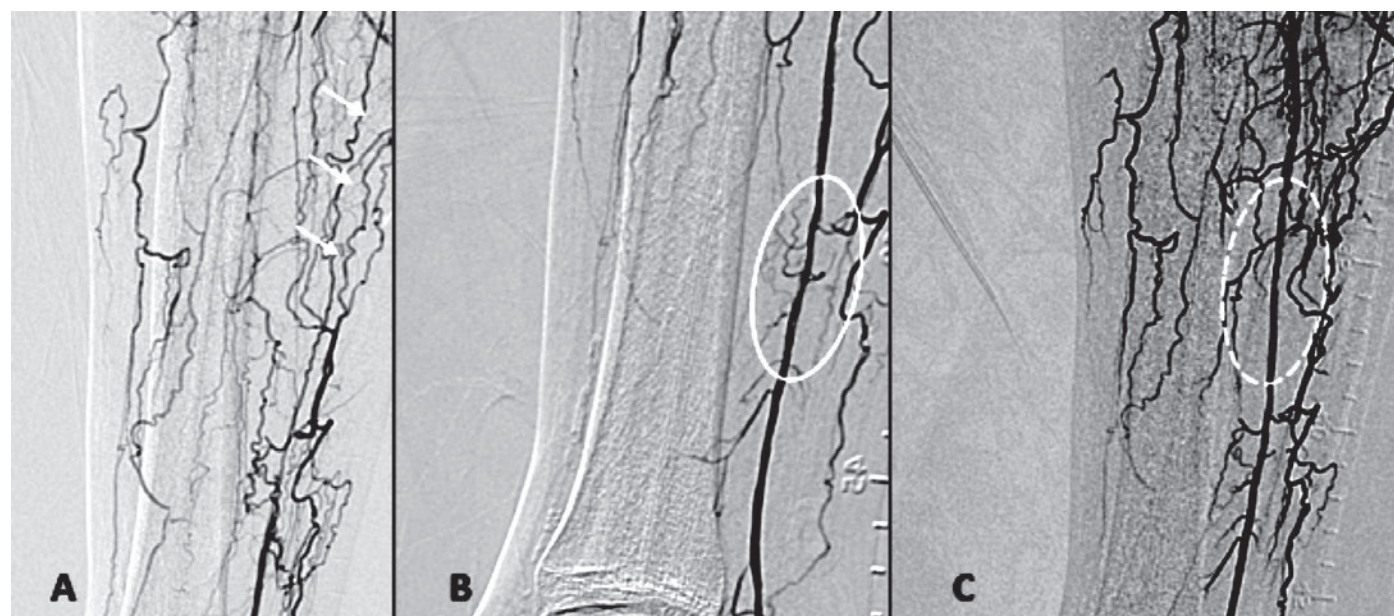


Figure. Posterior tibial occlusion (A, arrows) initially predilated with 2.0 mm PTA with residual stenosis (B, oval), subsequently treated with 2.5 mm PTA without residual narrowing (C, dashed oval).

has shown improved wound healing when compared to nontargeted bypass or angioplasty.¹⁰ However, the concept of angiosome-guided therapy is incomplete. Numerous factors may limit the applicability of the angiosome principle, including variations in tibial and pedal arterial anatomy, the presence or absence of an intact pedal loop, microcirculatory disturbances that impair collateral formation, and the presence of watershed regions with dual arterial perfusion.¹¹

Consequently, the targeting of tibial vessels for revascularization should more optimally be predicated upon a careful angiographic assessment, identifying which major obstructed tibial vessel(s) reconstitute flow to ischemic tissue in the foot either directly, via large collaterals, or via the pedal loop. This “angiographosome,” or angiographically mediated pattern of revascularization, requires selective distal injections, biplanar angiography, and the liberal use of vasodilators.

CONCLUSION

Tibial revascularization can be challenging, both cognitively (in the selection of device and treatment strategies) and anatomically (due to long, calcified, multivessel involvement). The appreciation of several key technical considerations can improve initial and long-term success. The epidemic nature of CLI, as well as the evolution of new devices and approaches to this complex disease process, will continue to challenge interventionalists for years to come.

Disclosure: Dr. Rundback reports consultancy to Medtronic | Covidien, CSI, and Bard. Dr. Herman reports reimbursements for education presentations from CSI, Bard, and Tenumo. Dr. Patel reports no related disclosures.

REFERENCES

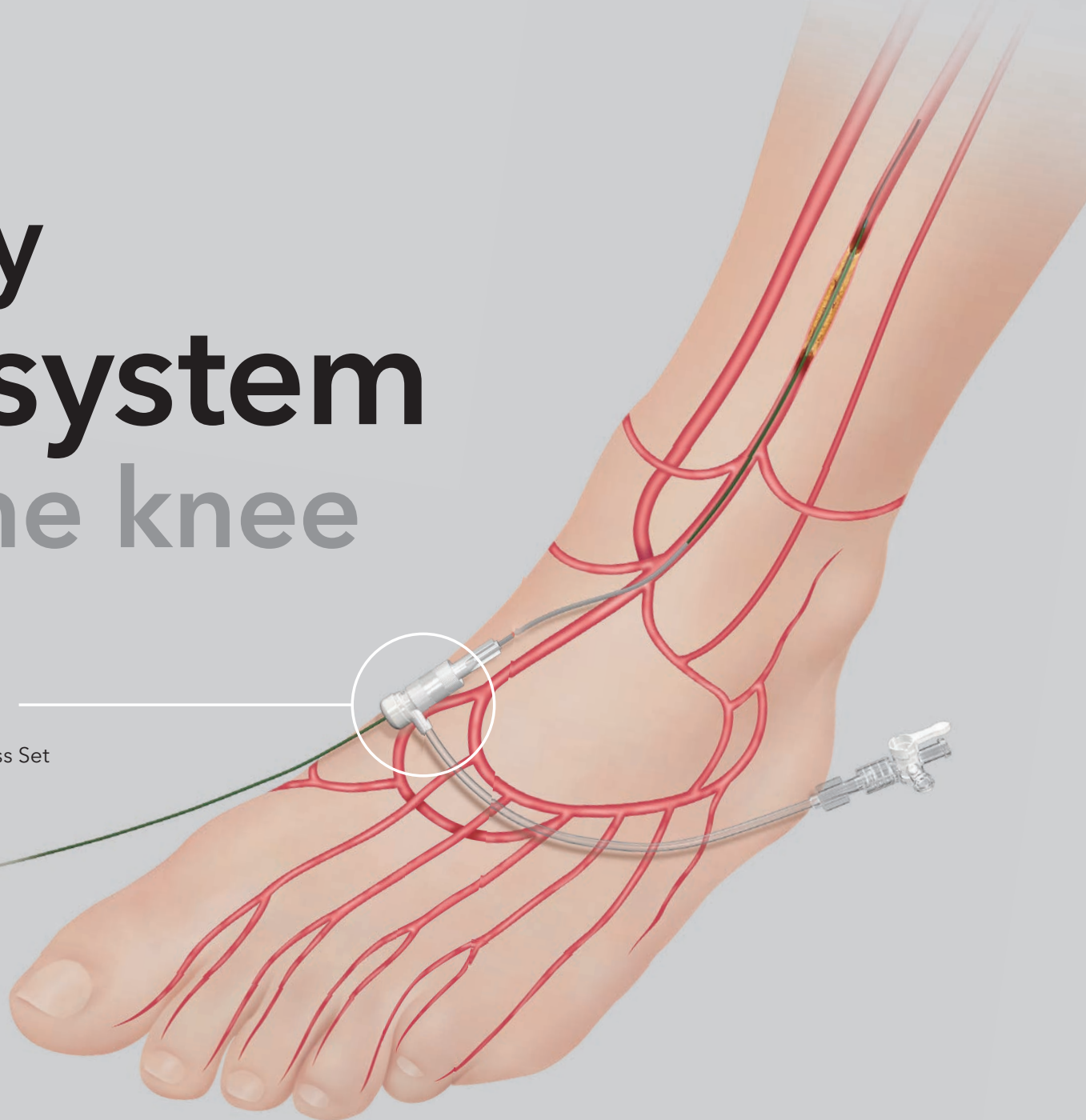
1. Castaneda-Zuniga WR, Formanek A, Tadavarthy M, et al. The mechanism of balloon angioplasty. *Radiology.* 1980;135(3):565-571.
2. Hanet C, Wijns W, Michel X, Schroeder E. Influence of balloon size and stenosis morphology on immediate and delayed elastic recoil after percutaneous transluminal coronary angioplasty. *J Am*

Coll Cardiol. 1991;18(2):506-511.

3. Baumann F, Fust J, Engelberger RP, et al. Early recoil after balloon angioplasty of tibial artery obstructions in patients with critical limb ischemia. *J Endovasc Ther.* 2014;21(1):44-51.
4. Zairins C, Lu CT, Gewertz BL, Lyon RT, Rush DS, Glagov S. Arterial disruption and remodeling following balloon dilatation. *Surgery.* 1982;92(6):1086-1094.
5. Dattilo R, Himmelstein SI, Cuff RE. The COMPLIANCE 360° Trial: a randomized, prospective, multicenter, pilot study comparing acute and long-term results of orbital atherectomy to balloon angioplasty for calcified femoropopliteal disease. *J Invasive Cardiol.* 2014;26(8):355-360.
6. Shamas NW, Lam R, Mustapha J, et al. Comparison of orbital atherectomy plus balloon angioplasty vs. balloon angioplasty alone in patients with critical limb ischemia: results of the CALCIUM 360 randomized pilot trial. *J Endovasc Ther.* 2012;19(4):480-488.
7. Das T, Mustapha J, Indes J, et al. Technique optimization of orbital atherectomy in calcified peripheral lesions of the lower extremities: the CONFIRM series, a prospective multicenter registry. *Catheter Cardiovasc Interv.* 2014;83(1):115-122.
8. Gray WA, Granada JF. Drug-coated balloons for the prevention of vascular restenosis. *Circulation.* 2010;121(24):2672-2680.
9. McMillan WD, Leville CD, Long TD, Gomes M, Groffsky JL, Schultz SR. Drug-eluting tibial stents: objective patency determination. *J Vasc Interv Radiol.* 2010;21(12):1825-1829.
10. McCallum JC, Lane JS 3rd. Angiosome-directed revascularization for critical limb ischemia. *Semin Vasc Surg.* 2014;27(1):32-37.
11. Kawarada O, Yokoi Y, Honda Y, Fitzgerald PJ. Awareness of anatomical variations for infrapopliteal intervention. *Catheter Cardiovasc Interv.* 2010;76(6):888-894.

The only 2.9 Fr system below the knee

Micropuncture®
2.9 Fr Pedal
Introducer Access Set



Compatible 2.9 Fr products

.014"



Approach CTO
Microwire Guide

2.3, 2.6 Fr



CXI®
Support Catheter

2.5 Fr



Advance Micro® 14
Ultra Low-Profile PTA
Balloon Catheter

TECHNOLOGIES FOR BELOW THE KNEE

2.9 FR
SYSTEM

The Use of Alternative Access in Calcified Tibial Vessels

Fadi Saab, MD¹; Larry J. Diaz-Sandoval, MD¹;

Andrej Schmidt, MD²; J.A. Mustapha, MD¹

From ¹Metro Heart and Vascular, Wyoming, Michigan, and

²University Clinic of Leipzig, Germany.



Fadi Saab, MD

The ability to safely gain arterial access is perhaps the most important step in the performance of routine and complex endovascular procedures. Advanced peripheral arterial disease (PAD) and critical limb ischemia (CLI) remain complex entities that pose a challenge in each step of revascularization, and establishment of direct blood flow to the infrapopliteal vessels is a must to achieve adequate revascularization in these patients. Endovascular revascularization could be broken down into 3 major steps:

1. Obtain arterial access.
2. Cross high-grade stenosis/chronic total occlusion (CTO).
3. Deliver therapy.

Traditionally, ultrasound (US) guidance has been used to obtain vascular access in venous conduits, and multiple trials have shown this approach to be safe and efficient.¹⁻³ In an attempt to decrease access-related complications, this technique has also been successfully used to guide traditional and tibial-pedal access in patients with CLI.⁴ The use of retrograde common femoral artery (CFA) access with “up and over” approach has been the “go-to” technique when treating long and complex CTOs in the superficial femoral artery (SFA); however, this approach has been trumped by failure rates of up to 40%.^{5,6}

These limitations, in conjunction with the increasing availability of disruptive technologies, have fueled the exploration of alternative access as a means to improve the success rates of endovascular

revascularization for patients with advanced PAD and CLI.

ALTERNATIVE ARTERIAL ACCESS

This category includes antegrade CFA as well as antegrade/retrograde popliteal, tibiopedal, and metatarsal access.⁷⁻¹⁰ In 2012, a technique consisting of puncture of the distal SFA and/or the proximal popliteal (P1) (distal to the reconstitution point) to cross SFA CTOs in retrograde fashion was described by Schmidt et al to treat patients with claudication (62%) and CLI (38%).¹¹ We have recently developed a modification of the latter approach whereby we directly access the occluded CTO segment in retrograde fashion. This report will offer a brief review of these alternative techniques for when tibial-pedal access is either not feasible or simply not enough.

FAILED ANTEGRADE APPROACH: TIBIAL-PEDAL NOT FEASIBLE. NOW WHAT?

Retrograde tibial-pedal access and interventions have been described as a useful technique to treat patients with advanced PAD and CLI.⁹ There are, however, certain limitations to the use of this approach such as the “White Stop Sign” (a term used to describe complete luminal obliteration of tibial vessels, as seen with US; Figure 1) and the “CAST” (CALcification Separating Tibial arteries), which describes the fluoroscopic appearance of medial calcification typically seen in tibial arteries around the ankle strap area. These areas of calcification are separated by “fractures” or gaps composed of fibrous tissue, which make intraluminal crossing of these areas very difficult (Figure 2) and represent areas with increased risk of perforation.

Even when able to obtain retrograde tibial-pedal access, many times we face heavily calcified and long CTOs in the femoropopliteal segment, which render pushing equipment from a tibial pedal site (small caliber) a futile effort. When faced with these limitations, alternatives are to be sought, especially in cases of limb salvage. The addition of an access point located in the middle of these long CTOs enables breakdown of the resistance vector in smaller segments, which in turn results in increased pushability and maneuverability of the devices used

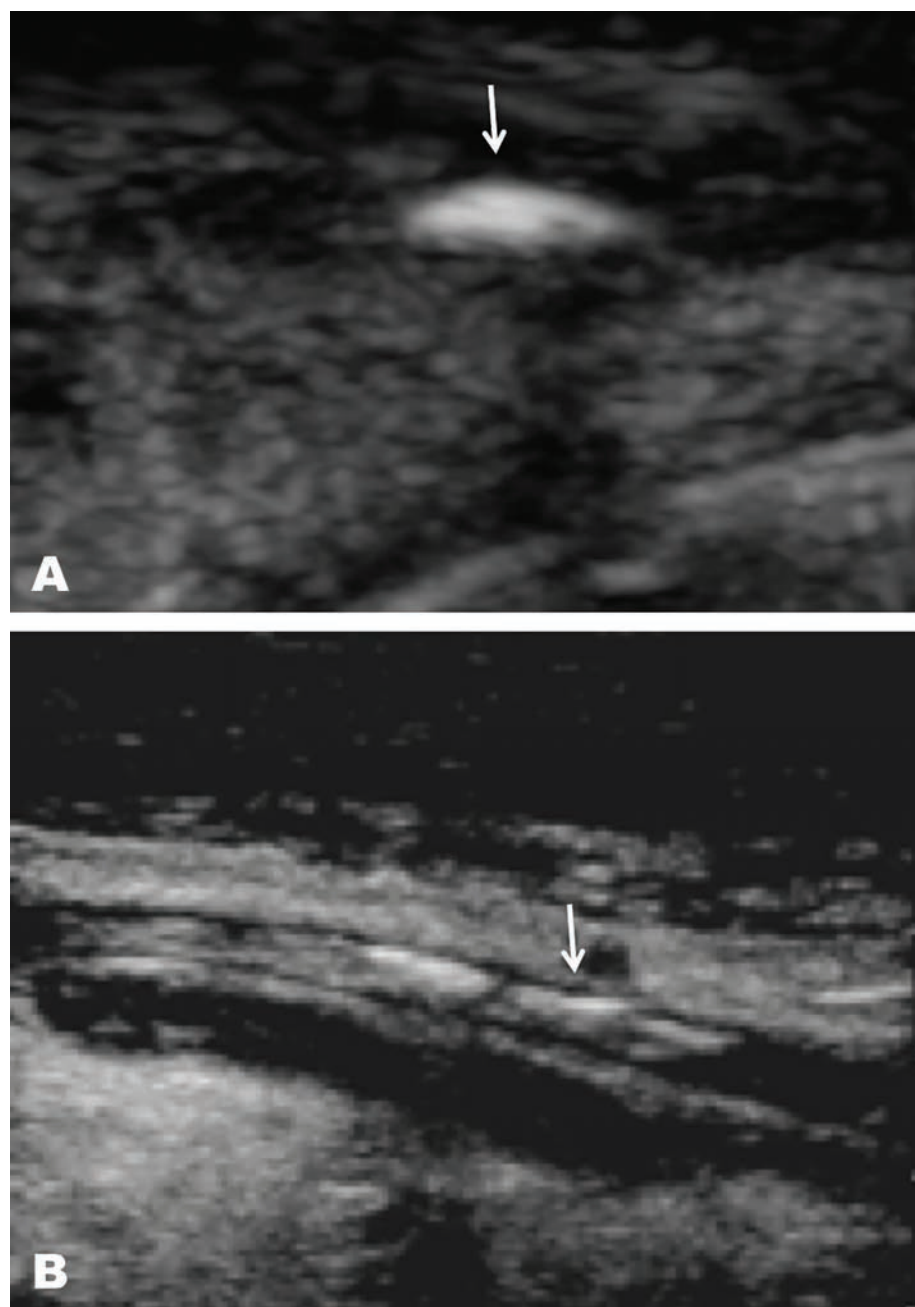


Figure 1. Short-axis view of the posterior tibial artery with completely obliterated lumen (A). Long-axis view of the completely obliterated lumen of the distal posterior tibial artery (B).

to cross and treat these lesions. While radial and brachial access might be helpful, these sites suffer from similar limitations, as they are far away from the area of interest and are hindered by the acute axilo-thoracic angle, decreasing the much-needed pushability. In view of these limitations, and the physics-based logic of breaking down a resistance vector into smaller segments, we describe the “Schmidt” technique, a modification of the original approach described by Schmidt et al, whereby we directly access into the CTO segment with US guidance, rather than into the reconstituted lumen.¹¹

THE SCHMIDT TECHNIQUE

Step 1: Access

Arterial access is obtained in retrograde fashion directly into the CTO, just proximal to the distal cap, in an effort to guarantee an intraluminal location (Figure 3). This can be done either under US or fluoroscopic guidance. When using US, the short-axis view is used to advance the needle into the lumen,

and once this is achieved, the probe is switched to the longitudinal access in order to visualize the wire penetration into the CTO. If fluoroscopic guidance is chosen, the C-arm is placed in a 30°–45° contralateral oblique projection to line up the needle with the vessel. As the needle is advanced, the C-arm is rotated to a 30°–45° ipsilateral oblique projection to determine the distance from the needle to the vessel. Once the needle is in the desired location (easily confirmed with US or fluoroscopy), use of an .018” wire (V-18 Boston Scientific) is recommended, in order to have enough support. Depending on the situation, a microsheath or a 4 Fr sheath can be utilized, or in selected cases, the access may be used to advance wires and catheters without introducers.

Step 2: Retrograde Crossing and Access Reversal

After sheath insertion, .018” or .035” support catheters may be used, accommodating different wire platforms. The

Continued on page 15

Alternative Access

Continued from page 14

use of 4 Fr sheaths may accommodate low-profile CTO crossing devices, such as the Viance (Covidien-Medtronic), and TruePath (Boston Scientific), to navigate the CTO in retrograde fashion. In cases where it is impossible to cross into the proximal true lumen, simultaneous antegrade-retrograde angioplasty may be performed as previously described¹¹ or re-entry devices could be also used. Once the antegrade and retrograde wires meet, the retrograde wire is snared from the antegrade access site (either an ipsilateral antegrade CFA or the traditional contralateral retrograde CFA with “up and over” approach) and the access is reversed.

Step 3: Therapy

Therapy is delivered in two steps. First, the segment between the proximal CTO cap and the “Schmidt” access point is treated with whichever modalities are considered necessary, including atherectomy, angioplasty, and stenting. A retrograde sheath in the distal SFA acts as embolic protection, preventing any clinically significant embolization. Then, the “Schmidt” access point must be crossed with either the antegrade wire or catheter combination or with a re-entry device.

Once this is achieved, the retrograde sheath is removed, leaving the wire in place in order to provide a “rail” to advance devices through the heavily calcified segment of the CTO and at the same time to serve as a hemostatic device. Then the intervention is finished in antegrade fashion, with attention paid to the need for a prolonged angioplasty that covers the access point (to achieve hemostasis).

Once a therapeutic device is across the Schmidt access point, the retrograde wire is removed. On some occasions, a third access (retrograde tibial pedal) is needed to cross the distal cap in retrograde fashion. The rest of the intervention is carried out following the previously described steps (access reversal and therapy delivery using whichever modality is considered necessary). Final hemostasis is achieved using a combination of intraluminal angioplasty across the Schmidt access point and a blood pressure cuff inflated at suprasystolic levels.

Antegrade CFA and tibiopedal access are gaining more acceptance among clinicians treating CLI patients.

DISCUSSION

Alternative access remains the foundation that operators performing complex procedures for patients with advanced PAD and CLI rely upon. Collaborations between physicians and industry have resulted in the creation of newer and disruptive technologies, which coupled with the development of newer techniques and approaches have increased the success rate of treatments and decreased the rate of procedure-related complications among this complex subset of patients. The uniqueness of the Schmidt technique described here is in the access of an occluded arterial segment proximal to the reconstitution, which offers several advantages:

1. Accessing an occluded segment decreases the chance of having an access site complication.
2. Breaking the long resistance vector into smaller components offers superior pushability, maneuverability, and ability to deliver therapy for complex, long, and calcified SFA CTOs, compared to that provided by retrograde tibial-pedal access and remote upper-extremity access.
3. This method avoids the need to use traditional popliteal access, which is effective but inconvenient, because the patient typically has to be repositioned during the procedure.^{10,12,13}

CONCLUSION

Alternative arterial access is a tool of paramount importance to cross and treat long and complex femoropopliteal CTOs in patients with advanced PAD and CLI. Antegrade CFA and tibiopedal access are gaining more acceptance among clinicians treating CLI patients. The Schmidt technique is one more tool in the armamentarium of the CLI specialist who spends time tackling complex CTOs. The availability of low-profile devices, including sheaths, catheters, wires, and CTO crossing devices, makes this technique easier to incorporate. The long-term benefit and efficacy of this approach should be the subject of further study in prospective registries.

REFERENCES

1. Randolph AG, Cook DJ, Gonzales CA, Pribble CG. Ultrasound guidance for placement of central venous catheters: a meta-analysis of the literature. *Crit Care Med*. 1996;24(12):2053-2058.
2. Milling TJ, Jr., Rose J, Briggs WM, et al. Randomized, controlled clinical trial of point-of-care limited

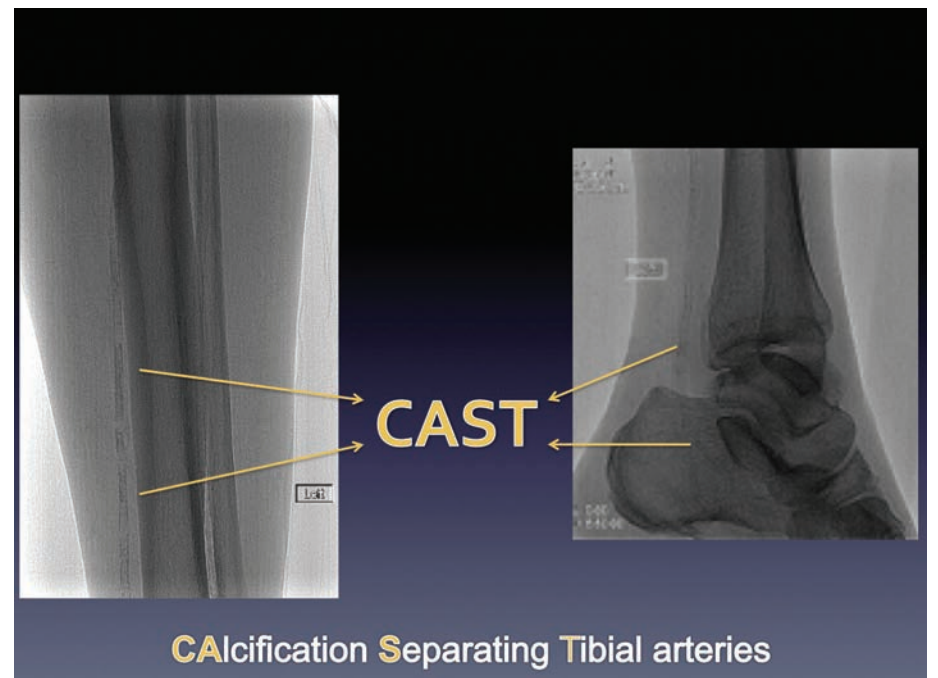


Figure 2. Arrows point to areas of “fracture” between CAST (CALcification Separating Tibial arteries) segments of diffuse circumferential medial calcification. The areas in between are composed of fibrous tissue.

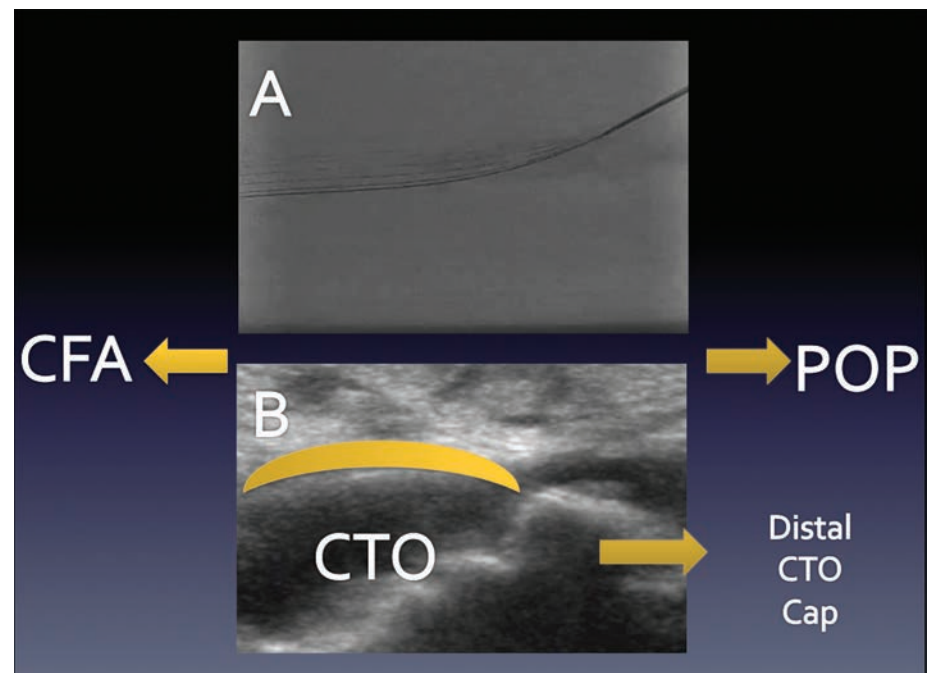


Figure 3. Fluoroscopic and ultrasound images of a chronic total occlusion (CTO) in the superficial femoral artery. Fluoroscopic image showing the needle through the occluded segment (A). Ultrasound image showing the distal CTO cap (B). CFA: common femoral artery. POP: popliteal artery.

- ultrasonography assistance of central venous cannulation: the Third Sonography Outcomes Assessment Program (SOAP-3) Trial. *Crit Care Med*. 2005;33(8):1764-1769.
3. Hind D, Calvert N, McWilliams R, et al. Ultrasonic locating devices for central venous cannulation: meta-analysis. *BMJ*. 2003;327(7411):361.
4. Mustapha JA, Saab F, Diaz L, et al. Utility and feasibility of ultrasound-guided access in patients with critical limb ischemia. *Catheter Cardiovasc Interv*. 2013;81(7):1204-1211.
5. Scheinert D, Laird JR, Jr., Schroder M, Steinkamp H, Balzer JO, Biamino G. Excimer laser-assisted recanalization of long, chronic superficial femoral artery occlusions. *J Endovasc Ther*. 2001;8(2):156-166.
6. Venkatachalam S, Bunte M, Monteleone P, Lincoff A, Maier M, Shishehbor MH. Combined antegrade-retrograde intervention to improve chronic total occlusion recanalization in high-risk critical limb ischemia. *Ann Vasc Surg*. 2014;28(6):1439-1448.
7. Feiring AJ, Wesolowski AA. Antegrade popliteal artery approach for the treatment of critical limb ischemia in patients with occluded superficial femoral arteries. *Catheter Cardiovasc Interv*. 2007;69(5):665-670.
8. Palena LM, Brocco E, Manzi M. The clinical utility of below-the-ankle angioplasty using “transmetatarsal artery access” in complex cases of CLI. *Catheter Cardiovasc Interv*. 2014;83(1):123-129.
9. Mustapha JA, Saab F, McGoff T, et al. Tibio-pedal arterial minimally invasive retrograde revascularization in patients with advanced peripheral vascular disease: The TAMI technique, original case series. *Catheter Cardiovasc Interv*. 2014;83(6):987-994.
10. Diaz-Sandoval LJ, Soukas PA. Popliteal arterial access. In RS Dieter, R Dieter III, R Dieter Jr, eds. *Endovascular Interventions*. New York: Springer Science. 2014;645-658.
11. Schmidt A, Bausback Y, Piorkowski M, et al. Retrograde recanalization technique for use after failed antegrade angioplasty in chronic femoral artery occlusions. *J Endovasc Ther*. 2012;19(1):23-29.
12. Noory E, Rastan A, Schwarzwald U, et al. Retrograde transpopliteal recanalization of chronic superficial femoral artery occlusion after failed re-entry during antegrade subintimal angioplasty. *J Endovasc Ther*. 2009;16(5):619-623.
13. Evans C, Peter N, Gibson M, Torrie EP, Galland RB, Magee TR. Five-year retrograde transpopliteal angioplasty results compared with antegrade angioplasty. *Ann R Coll Surg Engl*. 2010;92(4):347-352.

Selecting the Appropriate Endpoints in Critical Limb Ischemia Trials: More Challenging Than It May Appear

Anand Prasad, MD, FACC, FSCAI, RPVI*
From UT Health Science Center at San Antonio,
San Antonio, Texas.



Anand Prasad, MD, FACC, FSCAI, RPVI

For those of us who treat patients with critical limb ischemia (CLI), there is a conscious, and in fact often unconscious, personalization of medicine. We incorporate multiple variables into the treatment algorithm including anatomic assessment of vascular supply, degree of tissue loss, comorbid medical conditions, and even psychosocial issues. Our goals for individual patients vary — in some to close the ulcer and prevent any amputation, in others to minimize the level of amputation, and in yet others to heal stumps and flaps. While much of the approach is driven by evidence-based medicine, there remains an art to wound healing. Unfortunately, when designing and implementing research trials and registries, the multitude of variables that impact successful CLI outcomes become difficult to control for and the precise endpoints that are most relevant become challenging to define. The selection of appropriate endpoints also has implications for quality metrics, which are increasingly emphasized in modern health care systems.

OUTCOMES USED IN CLI STUDIES

A variety of endpoints either alone or in composite definitions have been used in clinical trials in the CLI population.¹⁻⁵ These outcomes include variables that are limb specific and those that are broader in their scope and include hard cardiovascular events. These former endpoints include

freedom from amputation, freedom from unplanned amputation, and wound healing/closure. Some studies have included

hard cardiovascular endpoints including death and many use amputation-free survival to capture morbidity and mortality. Secondary endpoints, particularly in revascularization-focused studies (either surgical or endovascular), have centered on safety, need for repeat intervention, and patency outcomes. Endpoints used in selected CLI studies are shown in Table 1.

We can categorize the endpoint assessments into patient outcome driven, anatomic/angiographic, and physiologic. Outcomes that are patient driven include quality of life, limb and gait preservation, reduction in time to wound healing, reduction of cardiovascular events, amputation-free survival, and overall mortality. Anatomic outcomes include vessel or graft patency, late loss (LL), and target lesion revascularization (TLR). Physiologic outcomes include changes in markers of perfusion, such as skin perfusion pressures

(SPP), transcutaneous oximetry measures (TCOMs), or changes in arterial Doppler derived velocities (change in peak velocities) and lower-extremity pressures (ankle or toe brachial index [ABI/TBI]).⁶

Ultimately, most of these endpoints have clinical relevance but as with any intervention in medicine, clinical endpoints trump surrogate markers — particularly from the patient’s perspective (Figure 1). Although physiologic measurements provide prognostic data and help with surveillance, they are seldom primary outcome measures. The role of anatomic endpoints remains even more controversial. In revascularization trials, vessel patency is often a key metric. The importance of patency — certainly in the longer term (>6-12 months from index procedure) — incites much consternation

Continued on page 17

Table 1. Selected Critical Limb Ischemia Trials and Included Endpoints

Trial	Description	Primary Endpoints	Other Key/Secondary Endpoints
BASIL ¹	Randomized controlled trial comparing efficacy of angioplasty vs open surgical bypass for patients with critical limb ischemia (CLI)	Amputation-free survival	• Postprocedural morbidity • Reinterventions • Health-related quality of life • Use of hospital resources
Prevent III ²	Randomized controlled trial evaluating efficacy of a molecular agent (edifoligide) to prevent vein graft failure in patients with CLI	• Time to nontechnical index graft reintervention • Major amputation due to index graft failure	• All-cause graft failure • Clinically significant graft stenosis • Amputation • Reintervention-free survival • Nontechnical primary graft patency
RESTORE-CLI ³	Randomized controlled trial of autologous bone marrow cells vs placebo for patients with CLI	Primary endpoints were safety related	Efficacy endpoints included in secondary outcomes: • Time to first occurrence of treatment failure (major amputation, death, doubling of wound total surface area from baseline) • Occurrence of de novo gangrene • Amputation-free survival • Incidence of major amputation • Wound healing
BEST-CLI ^{4,12}	Multicenter randomized trial comparing endovascular therapy with open surgical treatment in CLI patients eligible for both treatments	Major adverse limb event (MALE) free survival as defined by the Society of Vascular Surgery	• Amputation-free survival • Reintervention and amputation-free survival (RAFS) • Freedom from reintervention in the index leg • Number of reinterventions per limb salvaged • Freedom from clinical failure • Freedom from CLI • Freedom from all-cause mortality, freedom from hemodynamic failure • Functional and quality of life measures
IN.PACT DEEP ⁵	Randomized controlled trial comparing drug (paclitaxel) coated balloons versus non-coated balloons for treatment of infrapopliteal disease in CLI patients.	Two co-primary endpoints were assessed: • Clinically driven target lesion revascularization (CD-TLR) in the entire study cohort • Late lumen loss in a subgroup of subjects undergoing repeat angiography	The primary safety endpoint: • Composite of all-cause death, major amputation, and CD-TLR at 6 months

CLI Endpoints

Continued from page 16

in the field of CLI revascularization.⁷ The underlying current in this discussion actually reflects a more complex debate between endovascular therapies vs surgical revascularization.^{8,9} Studies have demonstrated that given an autologous vein and a suitable target, bypass outperforms a percutaneous transluminal angioplasty (PTA) approach in terms of vessel patency. However, multiple data sets reveal that limb salvage rates are comparable despite this finding.^{6,10} One might draw the conclusion, therefore, that patency is not important. While the majority of wounds heal within 3 months to 6 months with revascularization and appropriate wound care, nearly 30% to 40% may take longer.^{7,11} Restenosis or frank occlusion is a common finding in cases of stalled healing.⁷ Furthermore, even the term patency can be dissected and scrutinized. Patency can refer to primary patency, which evaluates the performance of the initial

intervention, assisted primary patency when additional intervention is needed to maintain patency, and secondary patency, when reintervention is needed for a subsequently occluded vessel. Patency or any variation of it is rooted in the surgical literature, where the presence of graft flow provided the criteria for patency. A patent but stenosed graft may still not provide adequate flow for healing. These considerations are even more challenging in the endovascular era, where much like cardiac stent trials there is a shift to outcome assessments with LL, TLR, or binary restenosis. How modern endovascular therapy (atherectomy, drug-coated technologies) might compete with surgical bypass remains to be tested. The ongoing BEST-CLI trial will provide further insights into the relationship of patency with outcomes between surgery and endovascular approaches.¹² Further complicating the use of patency as an endpoint is the fact that some patients may have lack of wound healing despite arterial patency, as additional factors such as infection, diabetic control, and status

of comorbidities may be overwhelming forces. Perhaps even more sobering are data that suggest that even with patency and successful limb salvage, a return to baseline functional status is often elusive in many patients.¹³

EFFORTS TO STANDARDIZE OUTCOMES IN CLI TRIALS

In an effort to standardize outcome reporting, several organizations have put together consensus documents to address the outcome issues. A major push to create standard outcomes in CLI therapy was undertaken by the Society of Vascular Surgery (SVS).¹⁴ This group was largely comprised of vascular surgeons and involved interactions with the US Food and Drug Administration (FDA). The objective performance goals (OPGs) were largely developed by examining the design and results of randomized, controlled trial data. The primary trials included the Project of Ex Vivo vein graft Engineering Via Transfection III (PREVENT III) trial,² the Circulase II trial,¹⁵ and the Bypass versus Angioplasty in Severe Ischemia of the Leg (BASIL) trial.¹ The OPGs were designed, in part, to provide benchmarks for single-arm device trial evaluations. The details of the SVS OPGs are available at <http://criticallimb.org>. Highlights of the recommendations included reporting acute periprocedural complications for both surgical and endovascular therapies: death, major adverse cardiac events, reinterventions, and amputation rates. The OPG recommendations for endovascular therapy include access complications (hematomas, fistulas), contrast-induced kidney injury, and distal embolization. Surgical outcomes included bleeding, need for reoperation, and surgical wound complications. In terms of longitudinal outcomes, trial duration in the context of CLI is recommended as 1 year. Two years is suggested as a potential

preference – largely on the 2-year BASIL trial data, which demonstrated potentially better survival with surgical therapy over angioplasty.¹⁶ The efficacy measures focus on death, amputation-free survival, freedom from clinical failure, and the composite endpoint of major adverse limb event (MALE), with this latter term encompassing amputation (below the knee or higher) and need for reintervention. Additional efficacy measures for wounds were incorporated, although less specific in nature as well as quality of life metrics. The role of these OPGs remains to be better defined, whether as premarket device benchmark tools, clinical trial endpoints, or practice performance goals.

Another effort to standardize definitions and provide some endpoint metrics comes from the Academic Research Consortium (ARC). The ARC is a largely cardiology-based group and has been instrumental in codifying definitions and measures of adverse events in cardiovascular trials, including stent thrombosis (ARC definitions), percutaneous valve technologies (VARC), and bleeding (BARC). The Peripheral Arterial Research Consortium (PARC) has been developed as a combined effort between multidisciplinary (vascular medicine, vascular surgery, cardiology, and radiology) academic groups in the United States, Japan, and Europe, along with industry and regulatory agencies, to address the need for concrete definitions in PAD trials.¹⁷ The specific goals of PARC include development of standardized definitions for clinical syndromes, anatomic designations, surrogate endpoints including physiologic and imaging measures, and symptomatic limb endpoints. The PARC has defined acute and longer term benchmarks for success of peripheral procedures. The clinical endpoints were based in part on the SVS recommendations and include MALE, defined as an above-ankle

Endpoints in Critical Limb Ischemia: Multiple Perspectives

What patients think about:

- Will this ulcer heal?
- Will I lose my leg?
- Will I ever walk again?
- Will I be able to go back to work?

What clinicians think about:

- Anatomy**
 - What is the inflow, outflow, pedal circulation?
 - What is the patency rate, TLR rate, late loss, binary restenosis rate?
- Physiology**
 - What is the tissue level perfusion?
 - What is the ABI and TBI?
 - What are the Doppler velocities and waveforms?
- Clinical**
 - What is the ulcer bed look like?
 - What is the size of the ulcer?
 - What level of amputation might be needed?
 - What is the patient's risk of death, myocardial infarction or stroke?
 - What is the patient's psycho-social status?
 - What is the patient's change in diabetic control, smoking cessation and risk factor modification?

Figure 1. Endpoints in critical limb ischemia: patient and physician perspectives.

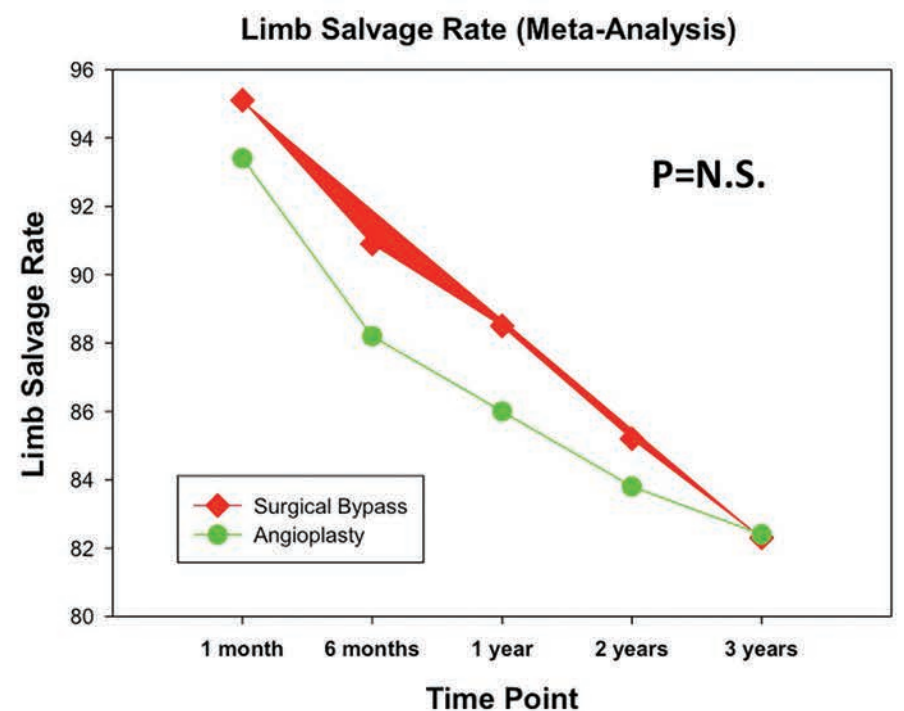
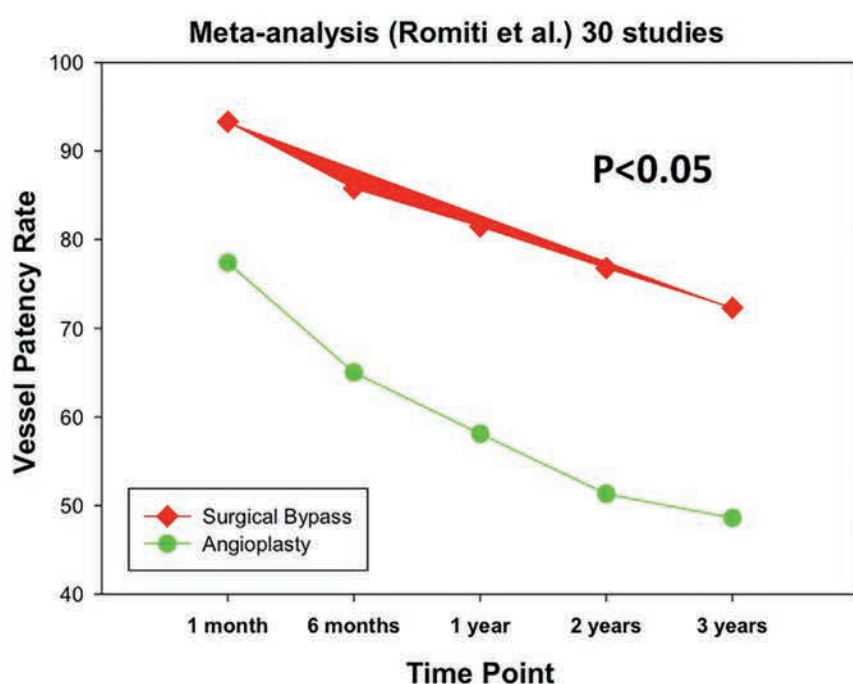


Figure 2. Meta-analysis of vessel patency and limb salvage rates, modified from Romiti et al.¹⁰

Continued on page 19

CLI Affects More Than the Legs: Upper-Extremity Critical Limb Ischemia

Abdul Bahro, MD, FACC, FSCAI¹, Nissa Mollema, PhD², and Brad Martinsen, PhD²

From ¹Merit Health Center, Jackson, Mississippi, and ²Cardiovascular Systems Inc., St. Paul, Minnesota.



Abdul Bahro, MD

Upper-extremity critical limb ischemia (UE-CLI) or critical hand ischemia (CHI) can be devastating and may potentially result in amputation.^{1,2} CHI may be caused by obstructions in above-the-elbow (ATE) arteries or in below-the-elbow arteries (BTE). Although lower-extremity CLI (LE-CLI) has been well studied and described in the literature, UE-CLI and CHI are rarely mentioned. Critical hand ischemia caused by chronic occlusive arterial disease is an uncommon condition and there is still no consensus concerning the most appropriate revascularization strategy.^{1,2} Surgical interventions for UE-CLI have focused on bypass grafting, often from the saphenous vein; however, these techniques are invasive and may result in a longer recovery time.³

Physicians are beginning to treat UE-CLI patients with percutaneous transluminal angioplasty before resorting to amputation.^{1,4,5} Atherectomy in the upper extremities is not typically considered due to the small anatomy; however, the Diamondback 360 Peripheral Orbital Atherectomy System (OAS) (Cardiovascular Systems, Inc.) can enter treatment areas with a reference vessel diameter of 1.5 mm. Here we describe 4 cases of radial artery occlusions treated with Diamondback OAS and balloon angioplasty.

CASE STUDY SERIES

Ten patients had calcific disease of the radial artery and UE-CLI/CHI. The first patient was a 47-year-old male, presenting with a necrotic right index finger (Figure 1) and a history of peripheral vascular disease; an occlusion was identified at the level of the wrist in the radial artery (Figure 2). The radial artery was treated with 1.25 mm Diamondback OAS crown and balloon angioplasty (2.5 mm to 3.5 mm x 60 mm to 220 mm, dilated 6 atm to 8 atm for 2 minutes), resulting in high blood flow to the hand (Figure 3). The wound healed by 4 weeks post procedure (Figure 4). Similar treatment was used for the other nine UE-CLI patients with radial artery occlusions and CHI.

A second case was a 57-year-old female with a history of stroke, hypertension, peripheral and coronary artery disease, amputations, and steal syndrome. She had severe disease at the proximal and distal anastomosis site of a jump graft to the left brachial artery. Her radial artery had very little flow.

In a third case, a 39-year-old male presented with gangrene in the first and second index fingers as well as a left below-the-knee amputation. Blood flow was slow through an occlusion in the patient's right radial artery. A fourth case was a 79-year-old male with end-stage renal disease and prior finger amputations. He had circumferential calcification of the radial artery. The other 5 cases had similar calcified radial artery occlusions.

RESULTS

All patients had good flow to the hand after intervention and did not experience any complications during or immediately after the procedures. The patients had positive long-term follow-up results and have not returned for repeat procedures on the lesions presented here.

Tips on Treating Upper-Extremity Critical Limb Ischemia

1. Make sure activated clotting time is therapeutic (~250).

Continued on page 19

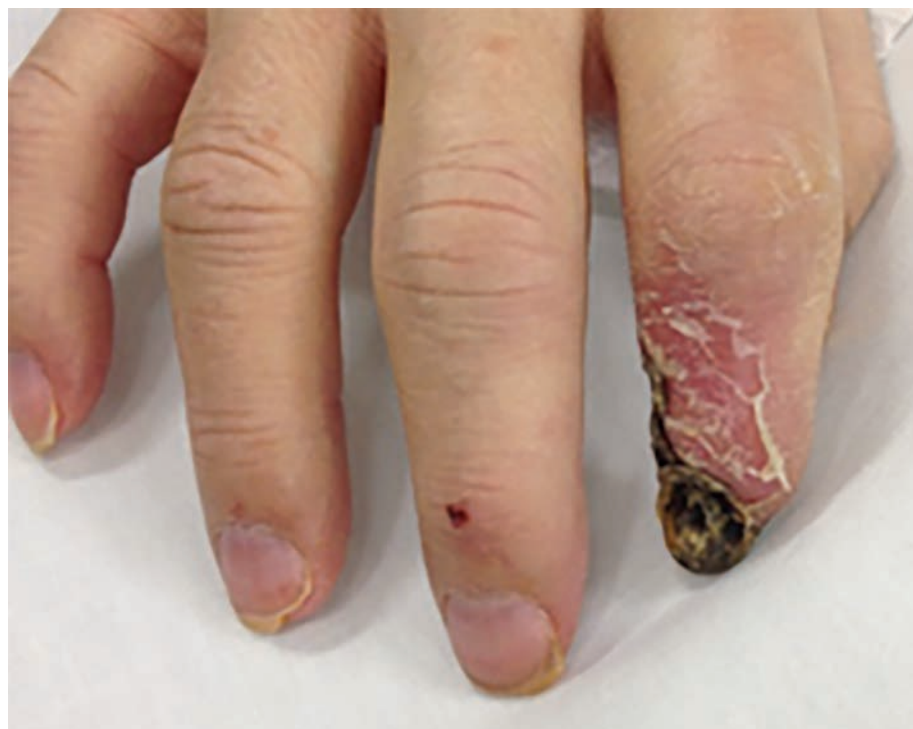

Figure 1. A 47-year-old male, presenting with a necrotic right index finger, upper-extremity critical limb ischemia, and chronic hand ischemia.

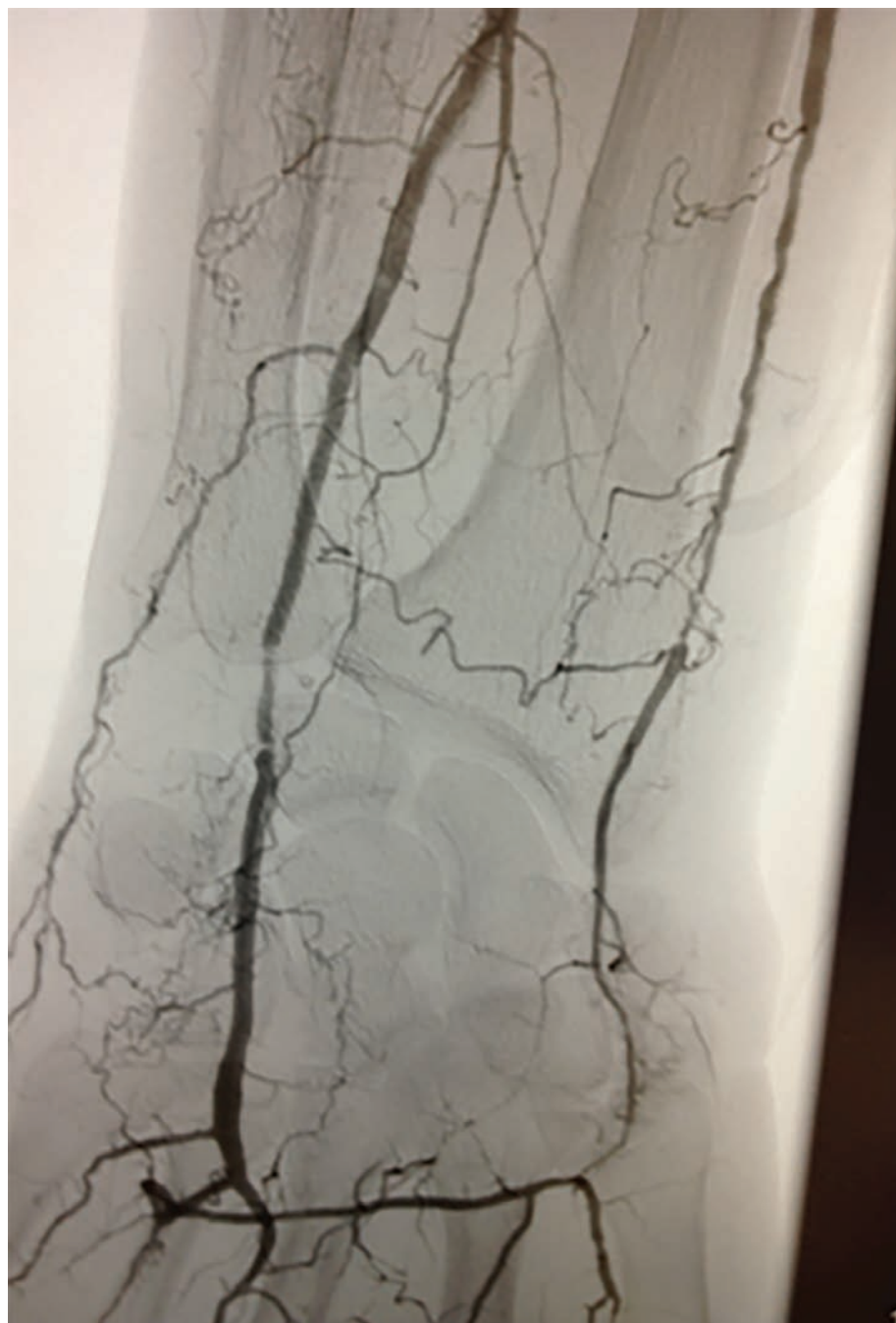


Figure 2. Angiogram indicating an occlusion at the level of the wrist in the radial artery.

Abdul Bahro, MD, Director of the Interventional Catheterization Laboratory, Merit Health Center, 1860 Chadwick Drive, Ste. 256, Jackson, MS, 39204. Abdul.Bahro@MyMeritHealth.com or abdulbahro@hotmail.com

CLI Endpoints

Continued from page 17

amputation of the index limb or major repeat revascularization of the target limb (new bypass graft, jump/interposition graft revision, repeat endovascular therapy, or thrombectomy/thrombolysis). Assessment of wound healing is recommended at 30 days to assess early response to therapy, with healing defined as complete epithelialization of an ischemic wound of target limb persistent for at least 14 days. Ischemic pain relief is defined as an improvement in (or relief of) pain of target limb for at least 2 weeks using visual analogue scale. This document was published in 2015 and therefore its impact on clinical trial design and device approval pathways remains to be determined.

TAKE-HOME POINTS

Healing of an ischemic ulcer and prevention of major amputation requires a multipronged and multidisciplinary approach. While there are many outcome

metrics that must be met along the way, a holistic approach and the patient's goals need to be kept in mind at each step of therapy. The use of composite endpoints — particularly MALE — is likely the future standard, as this outcome captures global and limb-specific data and allows for design of studies without the need for excessive sample sizes. The use of outcomes designed by consensus will need to be vetted in ongoing clinical trials such as the BEST-CLI study.

Disclosure: Dr. Prasad reports consultancy and grants from Osprey Medical as well as reimbursement for educational presentations from AstraZeneca and Gilead Medical. Dr. Prasad can be reached at prasada@uthscsa.edu.

REFERENCES

1. Adam DJ, Beard JD, Cleveland T, et al; BASIL trial participants. Bypass versus angioplasty in severe ischaemia of the leg (BASIL): multicentre, randomised controlled trial. *Lancet*. 2005;366(9501):1925-1934.
2. Conte MS, Bandyk DF, Clowes AW, et al; PREVENT III Investigators. Results of PREVENT III: a multicenter, randomized trial of edifoligide for the prevention of vein graft failure in lower extremity bypass

surgery. *J Vasc Surg*. 2006;43(4):742-751; discussion 751.

3. Powell RJ, Comerota AJ, Berceci SA, et al. Interim analysis results from the RESTORE-CLI, a randomized, double-blind multicenter phase II trial comparing expanded autologous bone marrow-derived tissue repair cells and placebo in patients with critical limb ischemia. *J Vasc Surg*. 2011;54(4):1032-1041.
4. Menard MT, Farber A. The BEST-CLI trial: a multidisciplinary effort to assess whether surgical or endovascular therapy is better for patients with critical limb ischemia. *Semin Vasc Surg*. 2014;27(1):82-84.
5. Zeller T, Baumgartner I, Scheinert D, et al. Drug-eluting balloon versus standard balloon angioplasty for infrapopliteal arterial revascularization in critical limb ischemia: 12-month results from the IN.PACT DEEP randomized trial. *J Am Coll Cardiol*. 2014;64(15):1568-1576.
6. Hiatt WR, Cox L, Greenwalt M, Griffin A, Schechter C. Quality of the assessment of primary and secondary endpoints in claudication and critical leg ischemia trials. *Vasc Med*. 2005;10(3):207-213.
7. Baumann F, Groechenig E, Diehm N. Does patency matter in patients with critical limb ischemia undergoing endovascular revascularization? *Ann Vasc Dis*. 2014;7(1):11-16.
8. Schamp KB, Meerwaldt R, Reijnen MM, Geelkerken RH, Zeebregts CJ. The ongoing battle between infrapopliteal angioplasty and bypass surgery for critical limb ischemia. *Ann Vasc Surg*. 2012;26(8):1145-1153.
9. Allie DE, Hebert CJ, Ingraldi A, Patola RR, Walker CM. 24-carat gold, 14-carat gold, or platinum standards in the treatment of critical limb ischemia: bypass surgery or endovascular intervention? *J Endovasc Ther*. 2009;16 Suppl 1:1134-1146.
10. Romiti M, Albers M, Brochado-Neto FC, Durazzo AE, Pereira CA, De Luccia N. Meta-analysis of

infrapopliteal angioplasty for chronic critical limb ischemia. *J Vasc Surg*. 2008;47(5):975-981.

11. Rocha-Singh KJ, Jaff M, Joye J, Laird J, Ansel G, Schneider P, Physicians V. Major adverse limb events and wound healing following infrapopliteal artery stent implantation in patients with critical limb ischemia: the XCELL trial. *Catheter Cardiovasc Interv*. 2012;80(6):1042-1051.
12. Farber A, Rosenfield K, Menard M. The BEST-CLI trial: a multidisciplinary effort to assess which therapy is best for patients with critical limb ischemia. *Tech Vasc Interv Radiol*. 2014;17(3):221-224.
13. Kumar BN, Gambhir RP. Critical limb ischemia—need to look beyond limb salvage. *Ann Vasc Surg*. 2011;25(7):873-877.
14. Conte MS, Geraghty PJ, Bradbury AW, et al. Suggested objective performance goals and clinical trial design for evaluating catheter-based treatment of critical limb ischemia. *J Vasc Surg*. 2009;50(6):1462-1473.
15. Brass EP, Anthony R, Dormandy J, et al. Parenteral therapy with lipo-ecraprost, a lipid-based formulation of a PGE1 analog, does not alter six-month outcomes in patients with critical leg ischemia. *J Vasc Surg*. 2006;43(4):752-759.
16. Bradbury AW, Adam DJ, Bell J, et al; BASIL trial participants. Bypass versus Angioplasty in Severe Ischaemia of the Leg (BASIL) trial: An intention-to-treat analysis of amputation-free and overall survival in patients randomized to a bypass surgery-first or a balloon angioplasty-first revascularization strategy. *J Vasc Surg*. 2010;51(5 Suppl):5S-17S.
17. Patel MR, Conte MS, Cutlip DE, et al. Evaluation and treatment of patients with lower extremity peripheral artery disease: consensus definitions from Peripheral Academic Research Consortium (PARC). *J Am Coll Cardiol*. 2015;65(9):931-941.

Upper-Extremity CLI

Continued from page 18

2. Use very gentle wire manipulation.
3. Utilize a small Diamondback OAS crown (1.25 mm).
4. Be aggressive with vasodilators and give through the exchange catheters.
5. Balloon size for angioplasty should match the size of the vessel. Complete long and low-pressure inflations. If a small area does not respond, use a smaller balloon with higher atmosphere inflation pressure.

DISCUSSION

The incidence of CHI due to BTE artery disease is difficult to assess, because most patients are treated conservatively and rarely identified.¹ BTE occlusions are more common in dialysis patients with symptoms of CHI and/or vascular access dysfunction.¹ In addition, calcification of the distal vessels of the upper extremities has been shown to be a major factor in causing hand ischemia.^{1,6,7} The improving survival time of end-stage renal disease patients suggests that UE-CLI and CHI may become a frequent problem in the future.¹ Thus, new treatment algorithms

are needed to properly diagnose and treat these patients.

CONCLUSION

Favorable outcomes can result from treating UE-CLI or CHI with endovascular techniques. Obtaining good outflow to the fingers is critical for wound healing. Orbital atherectomy is a useful tool in preparing vessels for balloon angioplasty, particularly in cases where calcification is present. Interventions in the radial artery may prevent or reduce the need for amputation of the fingers or hand. Although the radial artery has a small diameter, it can still be treated with orbital atherectomy, providing relief for patients with UE-CLI.

Disclosure: Dr. Bahro reports consultancy and travel reimbursements from CSI.

REFERENCES

1. Ferraresi R, Pallosi A, Aprigliano G, et al. Angioplasty of below-the-elbow arteries in critical hand ischaemia. *Eur J Vasc Endovasc Surg Off J Eur Soc Vasc Surg*. 2012;43(1):73-80. doi:10.1016/j.ejvs.2011.10.006.
2. Arabi M, Ahmed I, Qattan N. Transluminal recanalization of chronic total occlusion of radial artery using rendezvous technique: a case report and literature review. *J Clin Imaging Sci*. 2014;4:36. doi:10.4103/2156-7514.135663.
3. Weber R, Benacquista T, Suggs W, Herman CK, Strauch B. Palmar arch revascularization for arterial occlusion of the distal upper extremity. *J Reconstr Microsurg*. 2005;21(5):303-306. doi:10.1055/s-2005-871771.

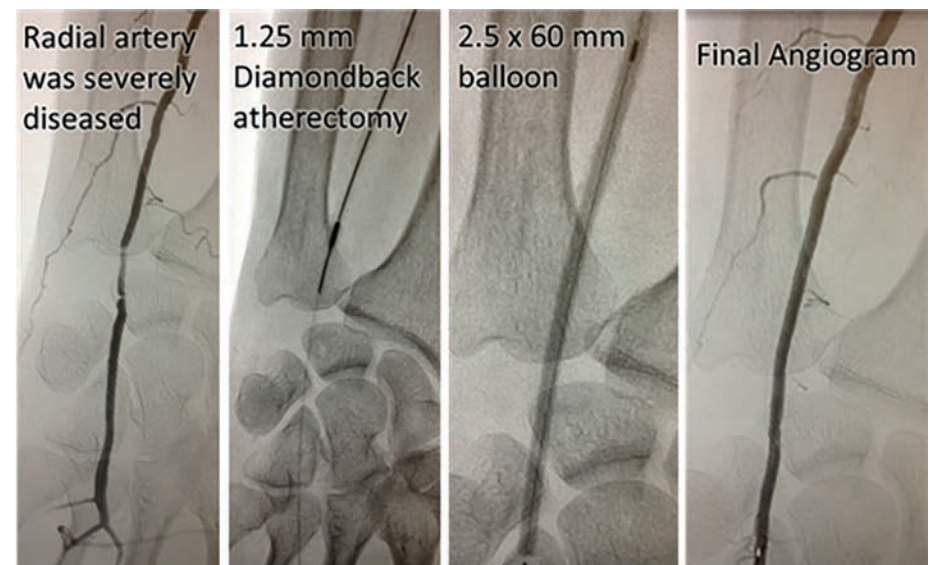


Figure 3. Radial artery occlusion was treated with 1.25 mm Diamondback OAS crown and balloon angioplasty.

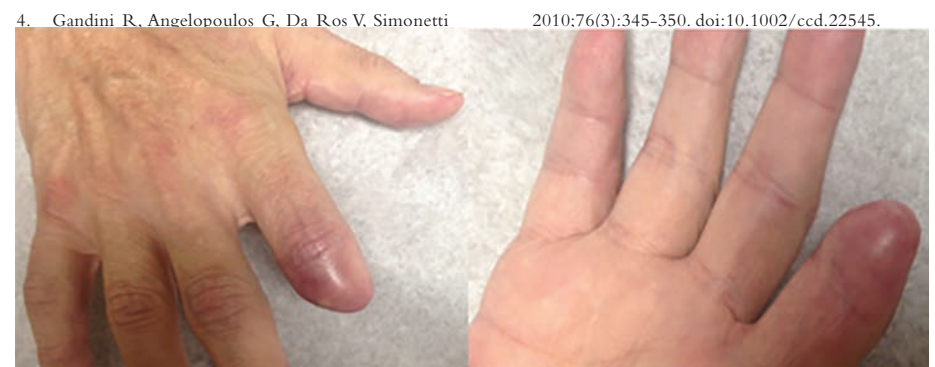

Figure 4. Complete wound healing by 4 weeks post procedure.

Interventions in the radial artery may prevent or reduce the need for amputation of the fingers or hand.

6. Percutaneous transluminal angioplasty for treatment of critical hand ischemia with a novel endovascular approach: "the radial to ulnar artery loop technique." *J Vasc Surg*. 2010;51(3):760-762. doi:10.1016/j.jvs.2009.07.067.
5. Kawarada O, Yokoi Y, Higashimori A. Angioplasty of ulnar or radial arteries to treat critical hand ischemia: use of 3- and 4-French systems. *Catheter Cardiovasc Interv Off J Soc Card Angiogr Interv*.

6. Yeager RA, Moneta GL, Edwards JM, et al. Relationship of hemodialysis access to finger gangrene in patients with end-stage renal disease. *J Vasc Surg*. 2002;36(2):245-249; discussion 249.
7. Derici U, El Nahas AM. Vascular calcifications in uremia: old concepts and new insights. *Semin Dial*. 2006;19(1):60-68. doi:10.1111/j.1525-139X.2006.00120.x.

Amputation or Not for Rutherford Class VI Patients: Is It Final?

Syed M. Hussain, MD, and Jennifer L. Ash, MD
From the Vein & Vascular Center, Christie Clinic,
Champaign, Illinois.



Syed M. Hussain, MD

Peripheral arterial disease (PAD) represents a wide array of presentations that range from asymptomatic PAD, stable symptomatic intermittent claudication, critical limb ischemia (CLI), acute limb ischemia, and amputation.¹ Critical limb ischemia is defined as PAD causing resting lower-extremity pain or with impending or overt tissue loss, and is classified as Rutherford Class IV–VI or Fontaine Class III and IV. Critical limb ischemia is a disease associated with high rates of cardiovascular morbidity and mortality.² It represents the end of the spectrum of PAD prior to major amputation.

Critical limb ischemia was first defined in published form in 1982. At that time, the term CLI was intended to be applied to patients without diabetes whose major threat to a limb was chronic ischemia. Critical limb ischemia was defined as an ankle pressure <40 mmHg in the presence of rest pain and <60 mmHg in the presence of tissue necrosis. In the cited document from 1982 describing the Rutherford classification system, the authors stated: “It was generally agreed that diabetic patients who have a varied clinical picture of neuropathy, ischemia and sepsis make definition even more difficult and it is desirable that these patients be excluded ... or should be clearly defined as a separate category to allow the analysis of the results in the nondiabetic patients.”³

Despite this cautionary verbiage, the use of the term CLI has been universally applied to a much broader spectrum of patients than originally intended. Because of the overly liberal application of the term CLI, efforts to measure and compare outcomes of different treatment options have been problematic, especially as revascularization options and other treatment approaches have rapidly expanded.⁴

Although CLI implies amputation without intervention, multiple studies have shown this not to be true. The CIRCULASE trial enrolled patients with rest pain and ischemic ulcers (Fontaine III and IV). The placebo arm demonstrated a 13% amputation rate at 6 months, with untreatable infection being the most common reason for major amputation.⁵ Furthermore, Marston reported on 142 patients with severe ischemia and wounds. Patients underwent meticulous wound care at a specialized center without revascularization. Major amputation rates at 6 and 12 months were 19% and 23%, respectively.⁶ These studies show that diabetic patients with wounds and without revascularization options cannot be deemed candidates destined for major amputation. Therefore, current classification systems such as Rutherford or TASC are inadequate to determine amputation risk, since only arterial lesions are taken into account.

The Society of Vascular Surgery (SVS) established the Lower Extremity Threatened Limb (Wound Ischemia foot Infection, or WIfI) Classification System in 2013 to gauge the risk that patients with critical limb ischemia (CLI) will require amputation. The goal of the system was to improve stratification of patients in clinical trials of CLI treatment. The WIfI system is based on wound extent, degree of ischemia, and extent of infection, with each graded on a scale of 1 to 3. Patients receive a spectrum score, with those considered at very low risk of limb amputation within 1 year classified as stage 1. Low-risk patients are classified as clinical stage 2 under the system, moderate-risk as stage 3, and high-risk as stage 4 (Figure 1). The researchers evaluated the system using data they had gathered prospectively on 139 patients with foot wounds who underwent a total of 158 revascularization procedures. Seventy-nine percent of the wounds healed, and the median time to healing was 2.7 months, with a range of one to 18 months. Diabetes mellitus, wound location, wound size, wound depth, and degree of ischemia were all associated with wound healing. Patients classified as stage 1 had a 3% likelihood of amputation at 1 year, stage 2 had a 10% chance, stage 3 a 23% chance, and stage 4 a 40% chance. Staging also predicted the risk of wound nonhealing, which was 8%, 10%, 23%, and 40%, respectively.⁴

Although the WIfI system takes into consideration both wound and infection characteristics, it remains a system that also overlooks several other variables that are

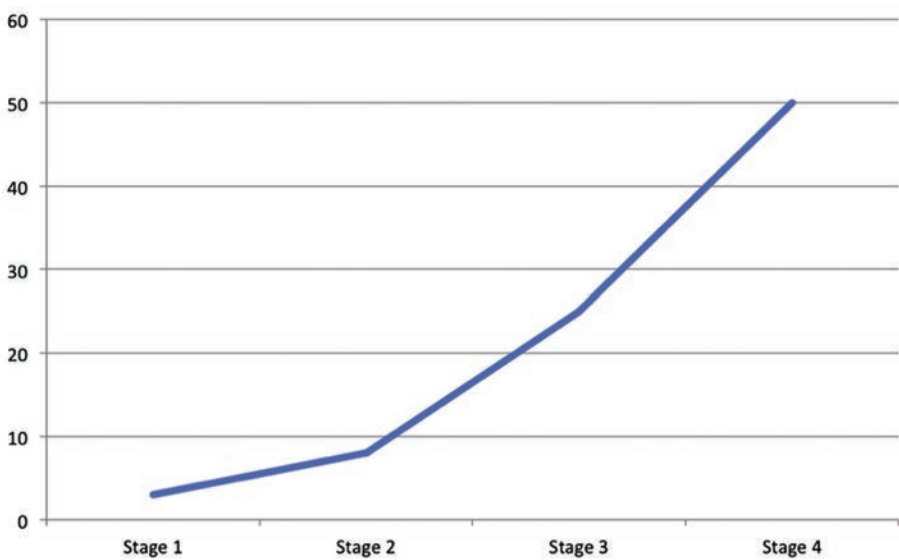


Figure 1. Estimated 1-year amputation risk (%) by Society for Vascular Surgery threatened limb clinical stage.

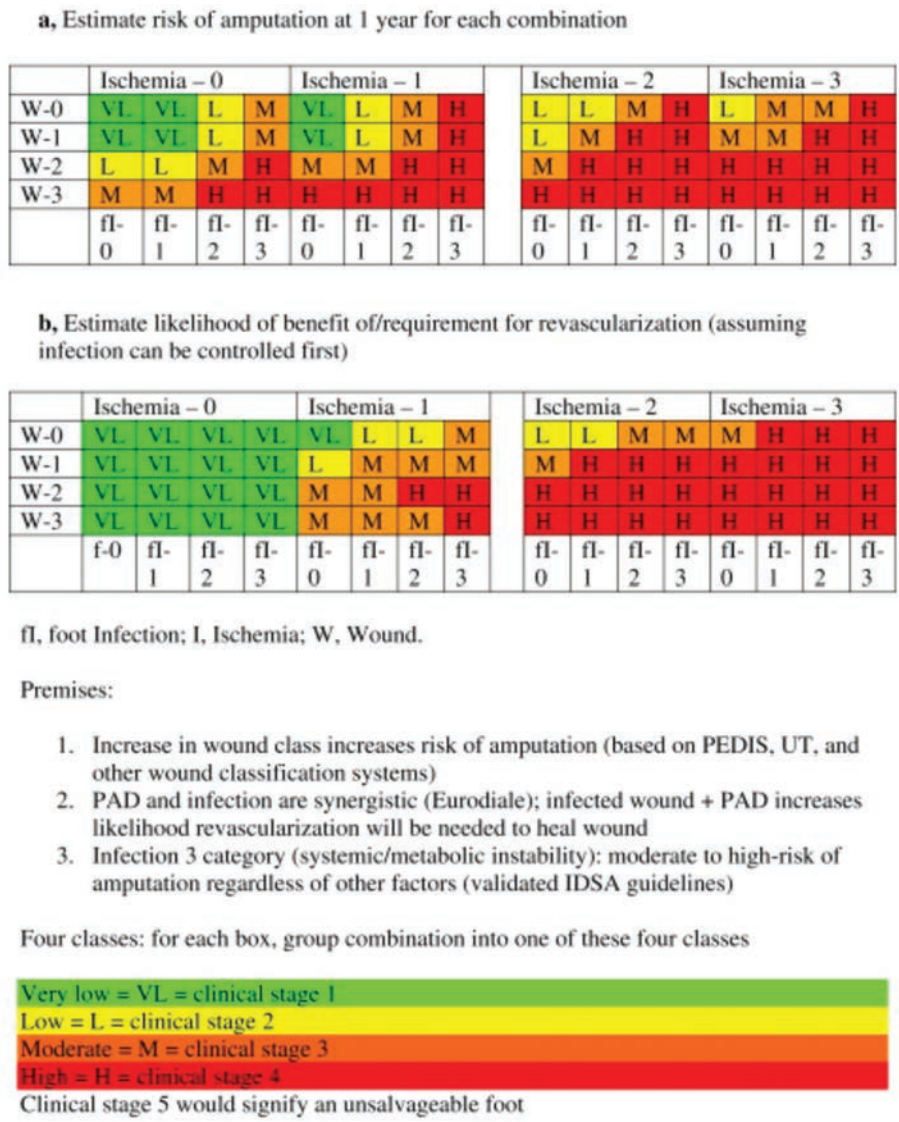


Figure 2. Risk/benefit: clinical stages by expert consensus.

frequently encountered in the PAD patient population: BMI,⁷ nutritional status,⁸ preoperative functional ability (Barthel Index),⁹ age, cognitive ability, and balance,¹⁰ to name a few. Thus, this classification system also has its limitations in determining limb salvage and amputation-free survival. Therefore, Rutherford Class VI disease is not an absolute indication for major amputation; on the other hand, Rutherford class VI is also not an absolute indication for

complex revascularization (surgical bypass vs endovascular therapy). As clearly illustrated, decisions regarding limb salvage cannot be made based on vascular anatomy alone, despite its clear contribution to patient outcomes. Decisions regarding revascularization vs major amputation require that we look beyond the Bypass vs Angioplasty in Severe Ischemia of the Leg (BASIL) and

Continued on page 22



ACHIEVE MORE TOGETHER

The perfect combination
for crossing complex lesions

Glidewire Advantage[®]

Peripheral Guidewires

Navicross[®]

Support Catheters

Pinnacle Destination[®]

Guiding Sheath

Committed to helping you do more

Learn about our hands-on training and expert clinical support.



Phone: 800.862.4143



terumo.com/together

For Rx only. Before using refer to **Instructions for Use** for indications, contraindications as well as warnings and precautions @ terumo.com

Amputation

Continued from page 20

Project of EX-Vivo Vein Graft Engineering via Transfection III (PREVENT III) trials. In the final analysis, a new and more in-depth classification system must first be developed to guide clinicians in determining which patients will benefit from revascularization and which patients will go on to major amputation.

Disclosure: The authors report no disclosures related to the content herein.

REFERENCES

1. Hirsch AT, Haskal ZJ, Hertzner NR, et al. ACC/AHA 2005 guidelines for the management of patients with peripheral arterial disease (lower extremity, renal, mesenteric, and abdominal aortic): executive summary a collaborative report from the American Association for Vascular Surgery/Society for Vascular Surgery, Society for Cardiovascular Angiography and Interventions, Society for Vascular Medicine and Biology, Society of Interventional Radiology, and the ACC/AHA Task Force on Practice Guidelines (Writing Committee to Develop Guidelines for the Management of Patients With Peripheral Arterial Disease)

- endorsed by the American Association of Cardiovascular and Pulmonary Rehabilitation; National Heart, Lung, and Blood Institute; Society for Vascular Nursing; TransAtlantic Inter-Society Consensus; and Vascular Disease Foundation. *J Am Coll Cardiol*. 2006;47(6):1239-1312.
2. Norgren L, Hiatt WR, Dormandy JA, Nehler MR, Harris KA, Fowkes FG; TASC II Working Group. Inter-Society Consensus for the Management of Peripheral Arterial Disease (TASC II). *J Vasc Surg*. 2007;45(1 Suppl S):S5-S67.
3. Bell PRF, Charlesworth D, DePalma RG, et al. The definition of critical ischemia of a limb. Working Party of the International Vascular Symposium. *Br J Surg*. 1982;69:S2.
4. Mills JL Sr, Conte MS, Armstrong DG, et al. The Society for Vascular Surgery Lower Extremity Threatened Limb Classification System: Risk stratification based on Wound, Ischemia, and foot Infection (WIfI). *J Vasc Surg*. 2014;59(1):220-234.
5. Brass EP, Anthony R, Dormandy J, et al. Parenteral therapy with lipo-craprost, a lipid-based formulation of a PGE1 analog, does not alter six-month outcomes in patients with

- critical leg ischemia. *J Vasc Surg*. 2006;43(4):752-759.
6. Marston WA, Davies SW, Armstrong B, et al. Natural history of limbs with arterial insufficiency and chronic ulceration treated without revascularization. *J Vasc Surg*. 2006;44(1):1008-1014.
7. Sohn MW, Budiman-Mak E, Oh EH, et al. Obesity paradox in amputation risk among nonelderly diabetic men. *Obesity*. 2012;20(2):460-462.
8. Boitano LT, Wang EC, Kibbe MR. Differential effect of nutritional status on vascular surgery outcomes in a Veterans Affairs versus private hospital setting. *Am J Surg*. 2012;204(5):e27-e37.
9. Eijk MS, van der Linde H, Buijck BI, Zuidema SU, Koopmans RT. Geriatric rehabilitation of lower limb amputees: a multicenter study. *Disabil Rehabil*. 2012;34(2):145-150.
10. Schoppen T, Boonstra A, Groothoff JW, de Vries J, Göeken LN, Eisma WH. Physical, mental, and social predictors of functional outcome in unilateral lower-limb amputees. *Arch Phys Med Rehabil*. 2003;84(6):803-811.

Lessons Learned

Continued from page 1

lesion revascularization of 87.3% for the stent group compared with 45.1% for the angioplasty group ($P<.0001$). Duplex ultrasound-derived primary patency at 12 months was better for the stent group (81.3% vs 36.7%; $P<.0001$).²

The DURABILITY trial showed that with bare metal stents in complex and calcified lesions with a mean lesion length of >9 cm, there was a primary patency rate of 72.2% at 1 year combined with a clinical improvement of 91.8%. Nevertheless, we have to face the problem of in-stent restenosis (ISR) in bare metal stents, which is a challenge for successful treatment options. Drug-eluting stenting (DES) as a treatment option was evaluated by the Zilver PTX trial and several subgroup trials using the paclitaxel-coated stent. In complex lesions in a Japanese trial, the Zilver PTX DES proved a primary patency rate of 50.2% and a freedom from clinically driven target lesion revascularization rate of 68.6%.³ Ultimately, Zilver PTX stent implantation for complex femoropopliteal artery disease did not affect long-term durability. The limit for this treatment option is the length of the stents (12 cm usable stent length) and the treatment of ISR if it is occurring.

Adhering to the philosophy of “leave nothing behind” is more and more challenging. It has resulted in the increased usage of drug-eluting balloons (DEB). Trials have proved the efficacy in SFA and popliteal lesions, and even in longer lesions. More data will be shown in the future from global registries. So far, we know from the INPACT SFA trial that we can gain a primary patency of 82.2% with the DEB compared to 52.4% in the POBA arm in SFA lesions associated with a gain of clinical improvement with the usage of DEBs in SFA lesions.⁴ The mean lesion length was 8.94 cm and the percentage of heavily calcified lesions was 8.1%. Results were reinforced by the LEVANT II data.⁵

In all the trials, calcium is the barrier for efficient drug penetration to the vessel wall. Treatment modalities to overcome these issues are mainly methods that prove that they are effective in removing the calcium from the vessel wall. Those modalities include well-known

procedures such as atherectomy as well as newer modalities such as the idea of disrupting calcium with lithoplasty.

A recent Cochrane review looked at atherectomy for SFA and popliteal artery treatment. Four trials were included with a total of 220 participants (118 treated with atherectomy, 102 treated with balloon angioplasty) and 259 treated vessels (129 treated with atherectomy, 130 treated with balloon angioplasty). All studies compared atherectomy with angioplasty. No study was properly powered or assessors blinded to the procedures, and there was a high risk of selection, attrition, detection, and reporting biases. The estimated risk of success was similar between the treatment modalities although the confidence interval (CI) was compatible with small benefits of either treatment for the initial procedural success rate (Mantel-Haenszel risk ratio [RR] 0.92, 95% CI 0.44 to 1.91, $P=.82$), patency at 6 months (Mantel-Haenszel RR 0.92, 95% CI 0.51 to 1.66, $P=.79$), and patency at 12 months (Mantel-Haenszel RR 1.17, 95% CI 0.72 to 1.90, $P=.53$) following the procedure. The reduction in all-cause mortality with atherectomy was most likely due to an unexpectedly high mortality in the balloon angioplasty group in one of the two trials that reported mortality (Mantel-Haenszel RR 0.24, 95% CI 0.06 to 0.91, $P=.04$). Cardiovascular events were not reported in any study. There was a reduction in the rate of bailout stenting following atherectomy (Mantel-Haenszel RR 0.45, 95% CI 0.24 to 0.84, $P=.01$), and balloon inflation pressures were lower following atherectomy (mean difference -2.73 mmHg, 95% CI -3.48 to -1.98 , $P<.00001$).

Complications such as embolization and vessel dissection were reported in two trials, indicating more embolizations in the atherectomy group and more vessel dissections in the angioplasty group, but the data could not be pooled. From the limited data available, there was no clear evidence of different rates of adverse events between the atherectomy and balloon angioplasty groups for target vessel revascularization and above-knee amputation. Quality of life and clinical and symptomatic outcomes such as walking distance or symptom relief were not reported in the studies. This review has

identified poor quality evidence to support atherectomy as an alternative to balloon angioplasty in maintaining primary patency at any time interval. There was no evidence for superiority of atherectomy over angioplasty on any outcome, and distal embolization was not reported in all trials of atherectomy. The conclusion of this Cochrane review was that properly powered trials are recommended.⁶

In the meantime, more actual data have been generated for atherectomy as shown by the DEFINITIVE Ca⁺⁺ trial. The proportion of asymptomatic subjects increased from 0% at baseline to 52.3% at the 30-day follow-up visit. In total, 88.5% of subjects experienced an improvement of one or more Rutherford categories.⁷ In the CONFIRM registry series, patients ($n=3,135$) undergoing orbital atherectomy (OA) by more than 350 physicians at over 200 United States institutions were enrolled on an “all-comers” basis. Treatment with OA reduced preprocedural stenosis from an average of 88% to 35%. Final residual stenosis after adjunctive treatments, typically low-pressure percutaneous transluminal angioplasty (PTA), averaged 10%. Plaque removal was most effective for severely calcified lesions and least effective for soft plaque.⁸

Lithoplasty is a new technology designed to disrupt calcium in peripheral vessels. Six-month data from the DISRUPT PAD trial were recently presented.⁹ Lithoplasty is a balloon-based technology that utilizes integrated lithotripsy, a pulsatile mechanical energy commonly used to break up kidney stones, disrupt both superficial and deep calcium, and normalize vessel wall compliance prior to low-pressure balloon dilatation. Lithoplasty is designed to be naturally gentle to soft tissue (non-diseased portions of the vessel) while remaining hard on calcium, the tissue that limits vessel expansion and the effectiveness of current technologies.

DISRUPT PAD is a single-arm, multicenter study evaluating the safety and utility of the Lithoplasty Balloon (Shockwave Medical) for the treatment of peripheral artery disease (PAD). The results from DISRUPT PAD demonstrate safe and effective dilatation of calcified stenosis with no acute failures, favorable residual stenosis, no major adverse

events, and no need for stent placement. At 6 months, freedom from reintervention was 100% and patency assessed by duplex ultrasound was 83%.⁹ Primary efficacy results demonstrated 100% success, defined as ability to achieve less than 50% residual stenosis using lithoplasty with or without adjunctive angioplasty. Device success was 87% using lithoplasty alone. The device achieved an average residual stenosis of 23% (initial 76%), with no difference in the ability to dilate lesions between moderate (36%) and severely (64%) calcified lesions.

CONCLUSION

Many different concepts are currently being investigated to fight the calcium burden in SFA disease, especially with the focus of drug use post procedure. The appropriate outstanding technology has not yet been found.

Disclosure: The author has completed and returned the ICMJE Form for Disclosure of Potential Conflicts of Interest. Dr. Brodmann reports no disclosures related to the content herein.

REFERENCES

1. Norgren L, Hiatt WR, Dormandy JA, Nehler MR, Harris KA, Fowkes FG et al. Inter-Society Consensus for the Management of Peripheral Arterial Disease (TASC II). *Eur J Vasc Endovasc Surg* 2007; 33(Suppl 1): S1-S75.
2. Laird JR, Katzen BT, Scheinert D, et al; for the RESILIENT Investigators. Nitinol stent implantation versus balloon angioplasty for lesions in the superficial femoral artery and proximal popliteal artery: twelve-month results from the RESILIENT randomized trial. *Circ Cardiovasc Interv*. 2010;3:267-276.
3. Fujihara M, Utsunomiya M, Higashimori A, Yokoi Y, Nakamura M. Outcomes of Zilver PTX stent implantation for the treatment of complex femoropopliteal artery disease. *Heart Vessels*. 2014 Oct 29. [Epub ahead of print]
4. Tepe G, Laird J, Schneider P, et al; INPACT SFA Trial Investigators. Drug-coated balloon versus standard percutaneous transluminal angioplasty for the treatment of superficial femoral and popliteal peripheral artery disease: 12-month results from the INPACT SFA randomized trial. *Circulation*. 2015 Feb 3;131(5):495-502.
5. Rosenfield K, Jaff MR, White CJ, et al; LEVANT 2 Investigators. Trial of a paclitaxel-coated balloon for femoropopliteal artery disease. *N Engl J Med*. 2015;373(2):145-53.
6. Ambler GK, Radwan R, Hayes PD, Twine CP. Atherectomy for peripheral arterial disease. *Cochrane Database Syst Rev*. 2014 Mar 17;3:CD006680. doi: 10.1002/14651858.CD006680.pub2. Review.
7. Roberts D, Niaz K, Miller W, et al; DEFINITIVE Ca⁺⁺ Investigators. Effective endovascular treatment of calcified femoropopliteal disease with directional atherectomy and distal embolic protection: final results of the DEFINITIVE Ca⁺⁺ trial. *Catheter Cardiovasc Interv*. 2014;84(2):236-244.
8. Das T, Mustapha J, Indes J, et al. Technique optimization of orbital atherectomy in calcified peripheral lesions of the lower extremities: the CONFIRM series, a prospective multicenter registry. *Catheter Cardiovasc Interv*. 2014;83(1):115-122.
9. Brodmann M. Six-month results of DISRUPT PAD. Presented November 5, 2014, at VIVA 2014, Las Vegas, Nevada.

Abstracts From the 5th Annual Amputation Prevention Symposium

Abstract 1: A Rare Cause of Critical Limb Ischemia in a Young Adult

Jagadeesh Kalavakunta, MD¹; Yashwant Agrawal, MD²; Elizabeth Sayers, PA³; Fadi Saab, MD³; J.A. Mustapha, MD³

From ¹Michigan State University; ²Western Michigan University; ³Metro Health Hospital, Wyoming, Michigan.

Atherosclerosis is the most common etiology of obstruction of the arteries leading to limb ischemia. When critical limb ischemia (CLI) presents in a young adult, the clinician should consider nonatherosclerotic diseases. We present a rare of cause CLI in a 35-year-old male who presented with Rutherford class VI symptoms of nonhealing gangrenous right great toe. His angiograms revealed medial type of fibromuscular dysplasia (FMD) of the popliteal and peroneal arteries with “string of beads” appearance. He underwent endovascular therapy requiring multiple attempts to complete revascularization of peroneal and anterior tibial arteries. In young adults with CLI, interventionalists need to consider FMD as a possible etiology.

Abstract 2: Does Cerebrovascular Disease Affect the Prognosis of Patients With Critical Limb Ischemia?

Gabriel C. Inaraja-Pérez, PhD¹; Herbert Tejada-Meza, MD¹; Ernest Spitzer-Cano, MD¹; Maria Júlvez-Blancas, MD¹; Irene Molinos-Arruebo, PhD¹; Alejandro Rodríguez-Morata, PhD²

From the ¹University Hospital Miguel Servet, Zaragoza, Spain, and ²University Hospital Virgen de la Victoria, Malaga, Spain.

Introduction: Critical limb ischemia (CLI) has a similar physiopathology to cerebrovascular disease, because in both conditions, arteries are affected. Sequelae from stroke can influence the decision to revascularize or not, and this could potentially elevate the amputation rate. **Objectives and Materials/Methods:** Members of the Neurology and Vascular Surgery Department have collected data on 265 patients during hospital admissions and follow-up related to the limb ischemia and neurologic status/variables. Data were recorded retrospectively (admissions) and prospectively (follow-up). A “per-patient” statistical analysis (descriptive and inferential) was performed using SPSS. **Results:** More than 20% of the patients (54/267) had a previous history of cerebrovascular ischemia and 64% (171/267) had diabetes. Hypertensions was present in almost 75% (200/267), and 61% (163/267) were or had been smokers. Dyslipidemia was also present in 33% of the patients (87/267). Cardiopulmonary comorbidities were often found (coronary disease in 22% and COPD in 13%). There were no differences regarding risk factors and comorbidities among patients with or without previous history of cerebrovascular disease (stroke or transient ischemic attack). Although patients in the “cerebral ischemia” group were more dependent in activities of daily living ($P=.002$, $RR=1.2$), statistical tests did not show any difference in the minor amputation rate ($P=.332$), major amputation rate ($P=.805$), or diagnosis of “no-option” CLI ($P=0.899$). **Discussion:** Although patients with history of cerebrovascular disease were more dependent in activities of daily living, we did not observe differences in major amputations, absence of revascularization options, or changes in prognosis when compared to patients without history of cerebrovascular events. Regardless of these results, appropriate assessment of carotid artery disease is encouraged in patients with CLI who plan to undergo a revascularization procedure, to prevent further complications.

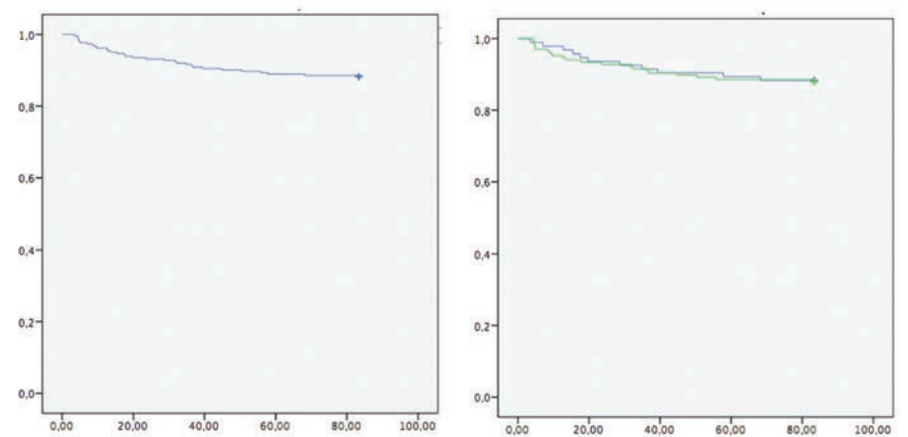


Figure 2. Time (months) from the diagnosis of CLI to the event of stroke/TIA, in the general population (left) and divided into option vs no-option critical limb ischemia.

Abstract 3: Chronic Limb Ischemia in the Upper Arms

Abdul Bahro, MD

From Cardiovascular Services of Central Mississippi, Jackson, Mississippi.

Introduction: Critical hand ischemia (CHI) can be devastating and may potentially result in amputation. The Orbital Atherectomy System (OAS) (CSI) can enter treatment areas with a reference vessel diameter of 1.5 mm. **Objective:** Five cases of CHI treated with OAS and balloon angioplasty are described here. **Methods:** The 5 patients ranged in age from 39 years to 79 years: all were referred with pain/ischemic changes to the hand and had typical comorbidities associated with vascular disease. Cases 1–4 had occlusions in the radial artery; case 5 had a brachial artery occlusion. In addition, case 3 had severe disease at the proximal and distal anastomosis site of a jump graft to the left brachial artery. The radial artery occlusions in patients 1–4 were treated with 1.25 mm OAS crowns and balloon angioplasty (2.5 mm to 3.5 mm x 60 mm 220 mm; dilated 6 atm to 8 atm for up to 2 minutes). The anastomosis site in case 3 was dilated with 3 mm x 40 mm balloons (up to 8 atm for 2 minutes). The brachial artery occlusion in case 5 was treated with a 2.0 mm OAS crown, 5 mm x 40 mm balloon, and 5 mm x 40 mm Supera Stent (Abbott). **Results:** All patients had good flow to the hand after intervention with no complications, and most had almost immediate relief of rest pain. The patients had positive long-term follow-up results and have not returned for repeat procedures on the lesions presented here. **Conclusion:** Interventions in the arm may prevent or reduce the need for amputations of the fingers or hand. These small-diameter vessels can be treated with atherectomy.

Abstract 4: Do Hybrid Revascularization Procedures Provide Any Benefit to Patients?

Maria Júlvez-Blancas, MD¹; Gabriel C. Inaraja-Pérez, PhD¹; Alejandro Rodríguez-Morata, PhD²; Irene Molinos-Arruebo, PhD¹; Ernest Spitzer-Cano, MD¹; Vicente Borrego-Estella, PhD¹; Lorena Colomina-Callén, MD¹

From the ¹University Hospital Miguel Servet, Zaragoza, Spain, and ²University Hospital Virgen de la Victoria, Malaga, Spain.

Introduction: Advances in endovascular materials and procedures provide the vascular specialist new tools to treat more patients. These techniques can also be used to optimize the inflow/outflow of open surgery in the same procedure. **Objectives and Materials/Methods:** Because these hybrid surgery procedures increase operating time and the “aggression” to the patient, we compared them to open surgery-only procedures to determine if there were any benefits to the patient or, on the contrary, if the addition of more techniques in a single-stage surgery increased the complication rate. **Results:** We collected data from 96 patients revascularized because of critical limb ischemia (CLI), 63 in the “open surgery” (OR) group (65.6%) and 33 in the “hybrid procedure” (HP) group (34.3%). Iliac percutaneous transluminal angioplasty (PTA) (36.4%) and femoropopliteal PTA (42.4%) were added to several open techniques (mainly femoral endarterectomy and femoropopliteal bypass). There were no differences in the characteristics of both groups regarding

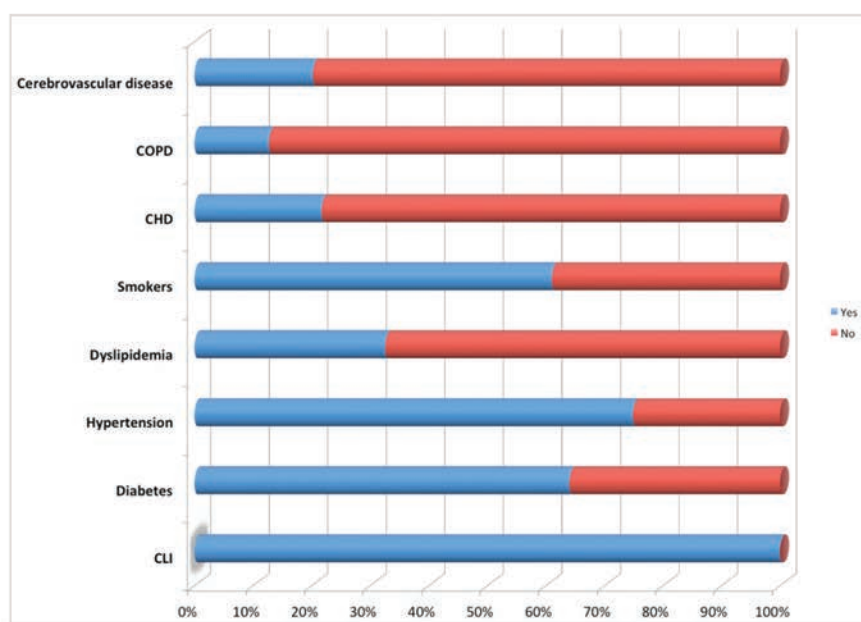


Figure 1. Risk factors in the population.

Table 1. Comparison of Both Groups

	Open surgery	Hybrid surgery	P
Age (y)	71,2	71,7	0.855
Length of stay (d)	44,9	37,1	0.083
Diabetes	58,7%	48,5%	0.338
CHD	14,3%	33,3%	0.029
COPD	12,7%	12,1%	0.935
Renal failure	22,2%	15,2%	0.409

Results: We collected data from 96 patients revascularized because of critical limb ischemia (CLI), 63 in the “open surgery” (OR) group (65.6%) and 33 in the “hybrid procedure” (HP) group (34.3%). Iliac percutaneous transluminal angioplasty (PTA) (36.4%) and femoropopliteal PTA (42.4%) were added to several open techniques (mainly femoral endarterectomy and femoropopliteal bypass). There were no differences in the characteristics of both groups regarding

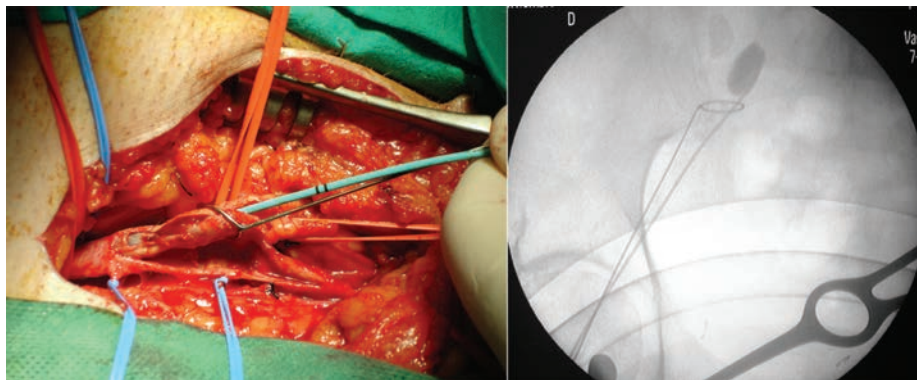


Figure 1. Femoral endarterectomy (left) and retrograde iliac endarterectomy prior to the deployment of a stent to fixate the proximal flap.

diabetes ($P=.338$), hypertension ($P=.172$), dyslipidemia ($P=.868$), smoking ($P=.774$), COPD ($P=.935$), renal insufficiency ($P=.409$), ASA risk ($P=.292$), rest pain ($P=.540$), or major tissue loss ($P=.183$). There were more patients with coronary heart disease in the hybrid group (33.3% vs 14.3%, $P=.029$). There were no differences in the amputation rate after surgery ($P=.122$) or the development of complications in hospital (acute renal insufficiency $P=.969$, wound healing issues $P=.227$, general major complications $P=.655$). Hospital admission time was not affected by a more aggressive revascularization and although not being statistically significant ($P=.083$), it was shorter in the HP group (37.1 vs 44.9 days). **Discussion:** The addition of an endovascular procedure to open surgery in a single-stage revascularization does not worsen the general outcome. It enables treatment of more patients (in comparison to open surgery only) and does not increase the complication rate.

Abstract 5: Is Age an Important Factor in Critical Limb Ischemia Today?

Maria Júlvez-Blancas, MD¹; Gabriel C. Inaraja-Pérez, PhD¹; Alejandro Rodríguez-Morata, PhD²; Irene Molinos-Arruebo, PhD¹; Vicente Borrego-Estella, PhD¹; Ernest Spitzer-Cano, MD¹; Virtudes Rico-Romero, MD¹
From the ¹University Hospital Miguel Servet, Zaragoza, Spain, and ²University Hospital Virgen de la Victoria, Malaga, Spain.

Introduction: Life expectancy is increasing due to health care improvements and better perioperative management. Patients are frequently older and have multiple comorbidities, both factors affecting clinical decisions (revascularization, amputation, medical treatment). Because this is becoming an everyday issue, we investigated whether age had a real impact in critical ischemia outcome or not. **Objectives and Materials/Methods:** 267 patients with critical limb ischemia (Rutherford class V-VI) were included in our study (admission between 2006 and 2010). Risk factors, comorbidities, and surgical interventions were recorded. Patients were divided into three groups depending on the age (<70, 70–75 and >75 years) to analyze if age was a predictive factor of the final outcome. **Results:** Patients under 70 years old were more often male ($P=.017$, RR=1.2), smokers ($P=.001$, RR=1.6) and had previously a PAOD (history of proven claudication, $P=.027$, RR=1.4). Patients under 80 had more endocrine disorders (diabetes [$P<.001$, RR=1.6] and dyslipidemia [$P<.001$, RR=2.3]). Despite these differences, the amputation rate (minor amputation [$P=.257$, $P=.289$, $P=.532$] and major amputation [$P=.958$, $P=.941$, $P=.332$]), and the primary amputation rate ($P=.231$, $P=.310$, $P=.677$) did not show any significant variation. **Discussion:** Analysis of the data shows that age is no longer a reason not to revascularize a patient; it is more important to assess the clinical presentation of the patient and make an individualized decision. Moreover, new endovascular devices allow interventionalists to treat more patients with a lower post-operative impact.

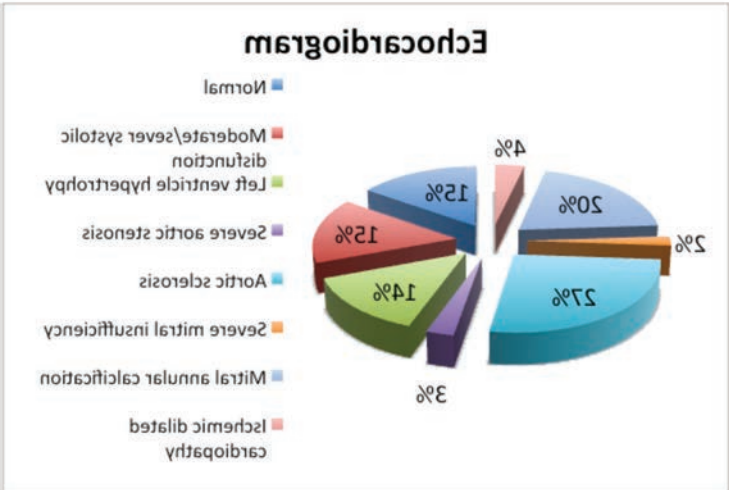
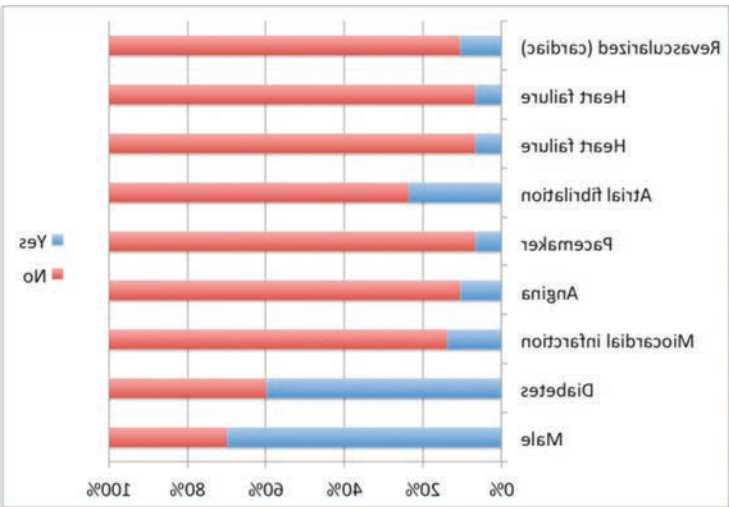
Table 1. Risk Factors in Patients Under 70 Years of Age			
Risk factors	< 70	> 70	P
Male	63/81 (77.8%)	117/186 (62.9%)	0.017
Smoker	66/81 (81.5%)	97/186 (52.2%)	<0.001
Previous claudication	45/81 (55.6%)	76/186 (40.9%)	0.027
No option CLI	30/81 (37%)	68/184 (37%)	0.990
Minor amputation	38/81 (46.9%)	73/185 (39.5%)	0.257
Major amputation	16/81 (19.8%)	36/185 (19.5%)	0.956
Primary amputation	6/81 (7.4%)	23/185 (12%)	0.231

Table 2. Risk Factors in Patients Under 80 Years of Age			
Risk factors	< 80	> 80	P
Diabetes	129/175 (73.7%)	42/92 (45.7%)	<0.001
Dyslipidemia	71/175 (40.6%)	16/92 (17.4%)	<0.001
CHD	30/175 (17.1%)	28/92 (30.4%)	0.012
No option CLI	66/173 (38.2%)	32/92 (34.8%)	0.589
Minor amputation	75/174 (43.1%)	36/92 (39.1%)	0.532
Major amputation	37/174 (21.3%)	15/92 (16.3%)	0.332
Primary amputation	18/175 (10.3%)	11/92 (12%)	0.677

Abstract 6: Should We Check the Heart Before Looking to the Limbs in Patients With Critical Limb Ischemia?

Gabriel C. Inaraja-Pérez, PhD¹; Ernest Spitzer-Cano, MD¹; Maria Júlvez-Blancas, MD¹; Alejandro Rodríguez-Morata, PhD²; Irene Molinos-Arruebo, PhD¹; Juan Pedro Reyes-Ortega, MD²; Vicente Borrego-Estella, PhD¹; Virtudes Rico-Romero, MD¹
From the ¹University Hospital Miguel Servet, Zaragoza, Spain, and ²University Hospital Virgen de la Victoria, Malaga, Spain.

Introduction: Peripheral artery disease (PAD) is an advanced manifestation of atherosclerosis closely related to coronary artery disease (CAD) and a proven marker of global atherosclerotic burden. Fontaine stage IV (F-IV) is the utmost manifestation of this condition with the highest risk of morbidity and mortality. When CAD is present, it constitutes a very limiting factor in terms of operating risk. Patients with advanced CAD have a higher risk of mortality and more frequently develop complications during hospital admissions. **Objectives and Materials/Methods:** The aim of this study was to evaluate the concomitant occurrence of cardiac diseases, including CAD, heart rhythm disorders (HRD), and structural heart disease (SHD) in patients first admitted for F-IV PAD. Cardiac data (ECGs, echocardiograms, and coronary angiographies, when available) were collected from 265 patients with CLI. **Results:** Almost 70% of patients (179/265) were male and more than 60% (171/265) suffered from diabetes. Thirty-seven patients (14%) had history of angina and 28 (10.6%) had had a myocardial infarction. Eighteen patients (6.8%) had a pacemaker, 63 (23.8%) had atrial fibrillation (AF), and 64 (6.8%) had heart failure. Revascularization had been performed in 10.7% of the patients (4.3% open, 6.4% endovascular). Echocardiogram was performed in 41.5% of patients, with the following findings: 25% were normal, 25.4% had moderate to severe systolic dysfunction, 22.7% had left ventricle (LV) hypertrophy, 4.6% severe aortic stenosis, 43.7% aortic sclerosis, 3.6% severe mitral insufficiency, 33.3% mitral annular calcification, 3.6% mitral stenosis, 1.8% severe tricuspid insufficiency, 3.4% pericardial effusion. No cardiomyopathies were detected in echocardiography except for ischemic dilated cardiomyopathy (6%), 1 patient had restrictive cardiomyopathy, and 1 patient had hypertensive cardiomyopathy. The mean pulmonary pressure was 41.7 mmHg. Coronary angiography was performed in 27 patients (10.2%). The studies were done prior to CLI admission in almost 75% of the patients (1.8 years before admission of CLI in 73.1% of the patients, and 2.3 years after CLI admission in 27%). Angiograms showed the presence of 3-vessel disease with severe calcification in 61.5% of the patients, with a mean number of lesions 4.1. **Discussion:** Coronary artery disease was the most frequent cardiac ailment in patients with Fontaine stage IV peripheral arterial occlusive disease, affecting 29% of individuals. Coronary angiography, when performed, showed complex multivessel disease. Atrial fibrillation was present in 24% of patients, and pacemakers were implanted in 7%. Significant valvular heart disease amounted to 13.6% of cardiac comorbidities. Nonischemic cardiomyopathies were uncommon. **Conclusion:** In patients with CLI, a comprehensive cardiac assessment should be performed as part of the work-up, including the initial exclusion of CAD and significant valvulopathies, since both are known predictors of mortality.



Abstract 7: What Factors Are Associated With No-Option Critical Limb Ischemia?

Maria Júlvez-Blancas, MD¹; Gabriel C. Inaraja-Pérez, PhD¹; Alejandro Rodríguez-Morata, PhD²; Ernest Spitzer-Cano, MD¹; Irene Molinos-Arruebo, PhD¹; Juan Pedro Reyes-Ortega, MD²; Vicente Borrego-Estella, PhD¹; Virtudes Rico-Romero, MD¹
From the ¹University Hospital Miguel Servet, Zaragoza, Spain, and ²University Hospital Virgen de la Victoria, Malaga, Spain.

Introduction:

Between 10% and 30% of patients diagnosed with critical limb ischemia (CLI) will not have the option of revascularization, leading inevitably to a conservative treatment. Sometimes amputation is necessary in cases of major tissue loss. **Objectives and Materials/Methods:**

A database was created based on 202 patients admitted (consecutive admissions due to CLI) to our hospital and included cardiovascular risk factors, previous interventions, ankle-brachial index (ABI), AngioCT, and angiography. A per-patient analysis was done to determine which factors were associated with no options of revascularization (NOCLI). **Results:** 80 patients of the 202 were diagnosed as “no option” (39.2%). There were no statistical differences between the two groups (“option” vs “no option”) in sex ($P=.609$), hypertension ($P=.290$), smokers ($P=.568$), coronary disease ($P=.232$), nephropathy ($P=.111$) and previous surgeries ($P=.970$). However, the following factors were associated with NOCLI: diabetes ($P=.016$, $RR=1.5$), fully dependent in activities of daily living ($P=.024$, $RR=1.5$), and low ABI (0.39 vs 0.46, $P=.028$). These patients were admitted for a longer period (42.8 vs 29.1 days, $P<.001$), suffered from more complications ($P<.001$, $RR=1.8$), and underwent amputation more often (major amputation, $P<.001$, $RR=26$). **Discussion:** Diabetes, being fully dependent in activities of daily living, and a low ABI are risk factors for a bad outcome in patients with critical limb ischemia, not only in terms of limb morbidity, but also regarding hospital stay and in-hospital complications.

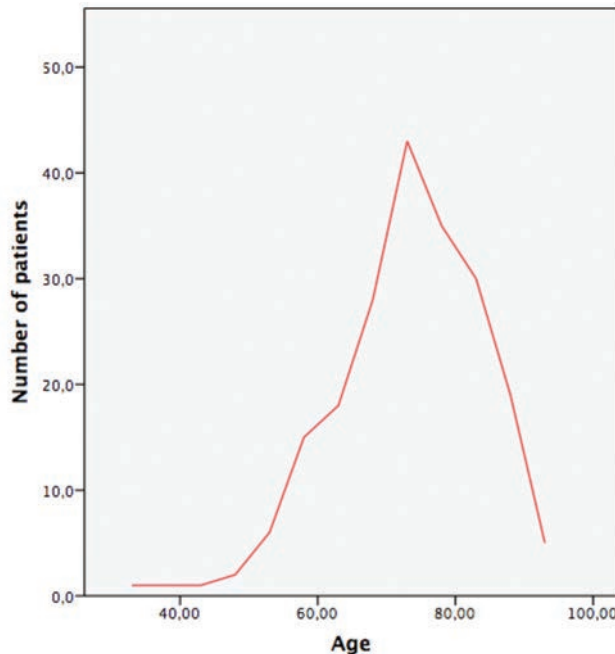


Figure. Patients by age.

Table. Risk Factors in Option and No-Option CLI Patients

	Option CLI	No-Option CLI	P
Diabetes	68 (55,7%)	58 (72,5%)	0,016
Hypertension	88 (72,1%)	63 (78,8%)	0,290
Dyslipidemia	44 (36,1%)	27 (33,8%)	0,736
Smoker	84 (68,9%)	52 (65%)	0,568
CHD	30 (24,6%)	14 (17,5%)	0,232
COPD	21 (17,2%)	7 (8,8%)	0,089
Renal failure	22 (18%)	22 (27,5%)	0,111
CVD	25 (20,5%)	11 (13,8%)	0,221
Dependence	43 (35,2%)	41 (51,2%)	0,024

Abstract 8: How to Close Large-Bore Sheaths With a Single Device, Leaving Nothing Behind

Rex Teeslink, MD

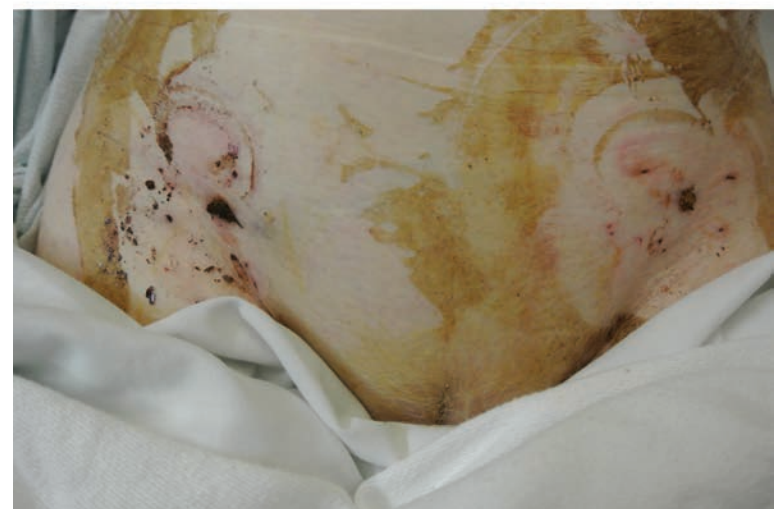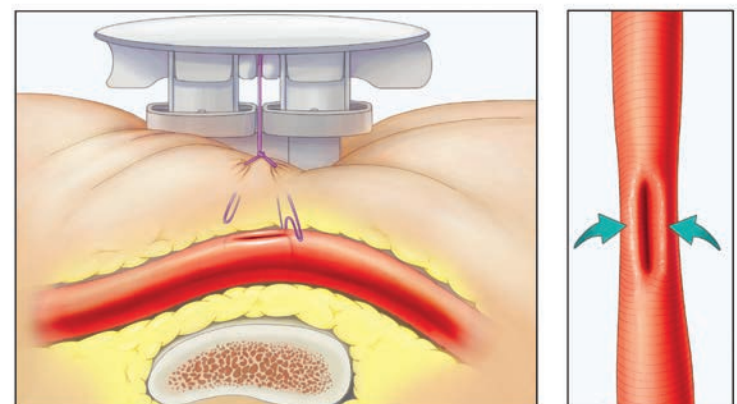
From Wound Care 360°, Olathe, Kansas.

Background: Wound Care 360 has designed a closure device, SiteSeal, which simulates external compression, but removes the associated variables. It applies invariant pressure to the vessel wall access site by utilizing internal stainless steel coils, which function as shock absorbers to dampen blood vessel pressure fluctuations. **Methods:** SiteSeal utilizes a number 2 Vicryl suture to make a Z stitch, which holds the SiteSeal device in place and closes the arteriotomy site in a linear fashion. The Z stitch is placed by entering the soft tissue at the skin insertion site of the sheath. If right handed, the first entrance is 1 cm east of the sheath, passing under the sheath and exits 1 cm west of the sheath. The second entrance is 1 cm above the skin insertion of the sheath and 1 cm to the east. The needle then crosses up and over the sheath and back down into the soft tissue and exits 1 cm west of the sheath. The two ends of the Z stitch form a double half knot, which when closed, creates an “X” over the arteriotomy site (see images). Bioseal powder is placed around the sheath and half knot. The device is cocked by turning the cross bar horizontally and applying pressure, which loads the springs. It is then centered over the sheath at the arteriotomy site with the incline plane facing north. The dilator is removed from the sheath. The two suture ends are pulled tight against the sheath as pressure is applied to the device, closing the Z stitch into an “X” over the arteriotomy site, and the sheath is removed. The suture ends are pulled up through the designed slots and tied into the notched slot of the cross bar. The loaded springs are released by turning the cross bar back to a vertical position. Once the device is activated, the pressure created by the Z stitch continues to elevate the artery and folds in the soft tissues surrounding the arteriotomy site, closing the site in a linear fashion. The roof is placed and Tegaderm is applied for stabilization. **Results:** 38 EVAR and 18 Impella procedures have been performed using SiteSeal without any hematoma formation at discharge, 24 hours, 7 days, and 30 days. **Conclusion:** SiteSeal has the ability to close large-bore sheaths with a single device, leaving nothing behind.

Associated advantages:

- Not limited by sheath size, including EVAR, TEVAR, TAVR
- No patient limitation: size, anticoagulation, calcification, etc.
- Simple and rapid deployment
- Allows immediate re-access
- Minimizes patient discomfort, allowing immediate head elevation to 30° with no restriction to leg movement
- Early ambulation
- Nothing left behind; the potential of minimal risk of vessel wall injury, infection, or embolization

Arteriotomy site with Site Seal in place, elevating artery and soft tissues, closing the arteriotomy



Abstract 9: Occlusion Perfusion Catheter (OPC): Next-Generation Treatment for Restenosis

Rex Teeslink, MD

From Advanced Catheter Therapies, Chattanooga, Tennessee.

Background: Advanced Catheter Therapies has designed the Occlusion Perfusion Catheter (OPC) to function as a universal agent-delivery system that will accommodate any therapeutic agent, including pharmaceuticals, biologics, and live cells. The OPC is a five-lumen catheter designed with proximal and distal occlusion balloons, a center space occupying balloon, an inflow port, an outflow port, and a guidewire lumen compatible with standard .014" sizes. It is a 5 Fr catheter compatible with a 6 Fr sheath. A fiber optic pressure sensor is incorporated into the inflow lumen to monitor treatment region pressure. Occlusion balloons define the treatment region. **Methods:** The proximal and distal occlusion balloons are inflated simultaneously to control blood flow and create a treatment chamber. In addition, they serve to prevent systemic distribution of the agent. The fourth and fifth lumens are for inflow and outflow ports located within the established treatment chamber. The trapped blood is removed from the treatment chamber by flushing with saline. The space-occupying balloon can be inflated to minimize the amount of therapeutic agent required, when indicated. This balloon never touches the vessel wall. Once the blood has been evacuated, the therapeutic agent is delivered. A sensor monitors, controls, and optimizes pressure within the chamber for penetration into the media of the vessel wall, longitudinally and circumferentially. **Preclinical Results:** Confocal analysis of the vessel wall demonstrated delivery of fluorescent paclitaxel within media and adventitial layer, circumferentially and longitudinally. Pharmacokinetic analysis demonstrated a straight line of 0.1 mcg/mL for 72 hours. According to Axel et al (*Circulation* 1997;96:636-645; Figure 2), the effective range of paclitaxel is 0.085-0.85 mcg/mL to affect a 90% to 99% inhibition of human arterial smooth muscle cells. Seven-day scanning electron microscopy demonstrated paclitaxel delayed healing effect. Twenty-eight-day histology demonstrated normal endothelium. Live cell testing demonstrated that the OPC can deliver live cells with minimal mechanical damage at a wide range of pressures. **Conclusion:** The OPC delivers an agent circumferentially and longitudinally into the vessel wall; delivers the effective range of paclitaxel for 90% to 99% inhibition of human arterial smooth muscle cells, maintaining normal intimal endothelial function by noncoating; delivers multiple agents; supports multiple use in the same patient, above and below the knee; delivers live cells with minimal mechanical damage to the cell membrane; negates blood/agent admixture; minimizes systemic effect via flushing; and decreases cost.

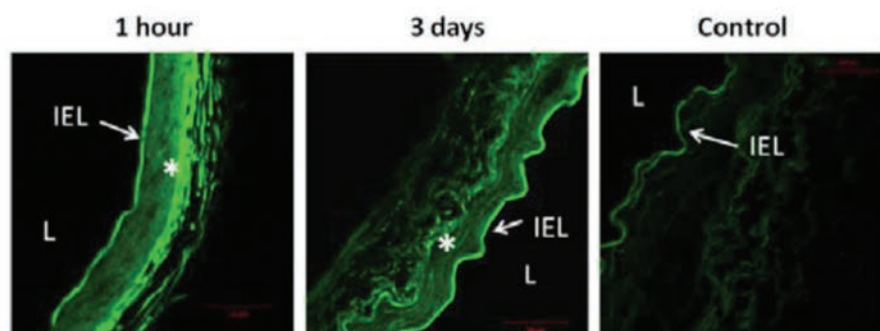


Figure 1. OPC performance in rabbit model study.

The Results: Pre-Clinical – PK Analysis

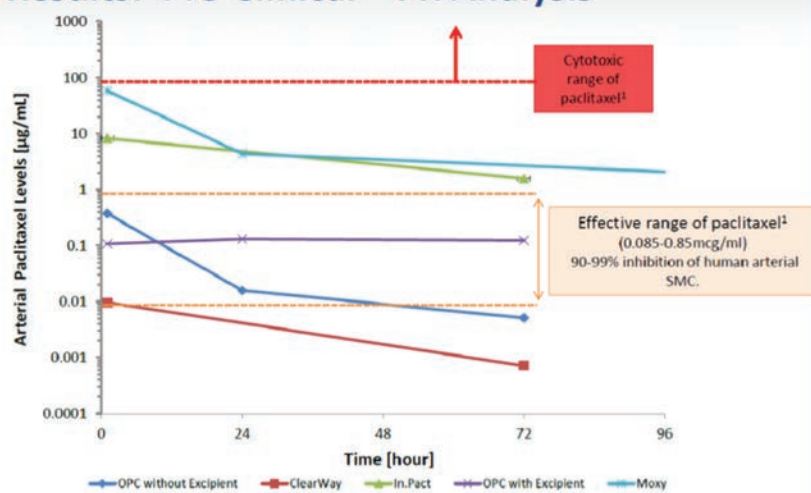


Figure 2. Preclinical pharmacokinetic analysis.

Abstract 10: Effect of Porcine Intestinal Submucosa Matrix on the Healing Rate of Stage IV Trunk Pressure Wounds

Abdelfatah Abou Issa, MD¹; Karen Brown, RN²; David Cool, PhD¹; Richard Simman, MD¹

From ¹Boonshoft School of Medicine at Wright State University, Fairborn, Ohio, and ²Kettering Network, Dayton, Ohio.

Introduction: Oasis Ultra (Smith & Nephew) is an extracellular collagen-rich matrix derived from porcine intestinal submucosa. A prospective, randomized, blinded clinical trial was conducted to study the effect of Oasis Ultra combined with negative pressure wound therapy (NPWT) on the healing rate of stage IV pressure wounds compared to NPWT alone. **Materials and Methods:** Twelve subjects were involved in the study, 6 study and 6 control. Negative pressure wound therapy was changed twice a week for all subjects and Oasis Ultra was applied weekly. The wounds were measured weekly and the healing rate was calculated for each subject for 12 weeks. The canisters were collected monthly for 3 months. Vascular endothelial growth factor (VEGF), fibroblast growth factor (FGF), platelet-derived growth factor (PDGF), and IL-1 & IL-6 were analyzed. **Results:** In the study group, the healing rate calculated at 12 weeks was found to be 83.37%

when compared to the control group, which was 47.66% only. The initial analysis of growth factors demonstrated higher concentrations in the study group when compared with control. **Conclusion:** These preliminary results demonstrate an increased healing rate of the stage IV pressure wounds in the Oasis Ultra and NPWT group when compared with NPWT only control group.

Abstract 11: Clinical Usage Outcome of Porcine Intestinal Submucosa, a Case Series

Abdelfatah Abou Issa, MD; Walid Mari, MD; Richard Simman, MD

From Boonshoft School of Medicine at Wright State University, Fairborn, Ohio.

Introduction: Porcine intestinal submucosa matrix is an extracellular collagen-rich matrix derived from submucosa of porcine intestine. It is composed of collagen type I, glycosaminoglycan, and proteoglycans. Our case series study has shown the promising effect of porcine submucosa matrix in healing of different kind of wounds. **Objective:** To test the clinical outcome of porcine submucosa matrix when used in a variety of wounds with different etiologies. **Materials and Methods:** This was an observational case series with prospective review of 5 different patients with different types of wounds who received this collagen-rich matrix (submucosa of porcine) during their treatment. **Results:** The first case was a diabetic patient with complicated transmetatarsal amputation of gangrenous left forefoot with flaps closure. A total of 3 applications over the period of 2 months were needed to heal his wounds. The second case involved a patient with a nonhealing right leg ulcer. The pathology revealed Marjolin's ulcer (squamous cell carcinoma). After clearing the margins, 2 applications of submucosa porcine matrix were needed over the period of 6 weeks to heal the wound. The third case involved an anticoagulated patient with right-hand traumatic hematoma. Surgical debridement was done, leaving her with exposed extensor tendons. One application of submucosa porcine matrix was

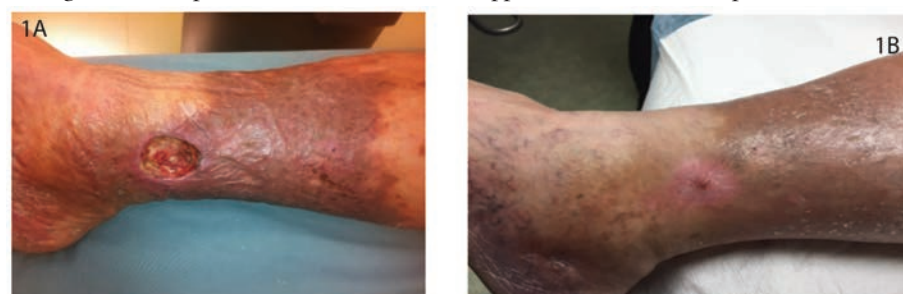
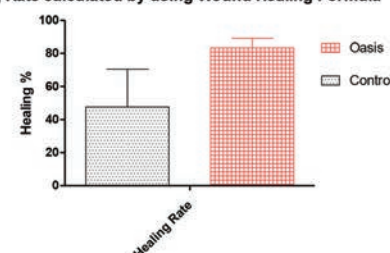
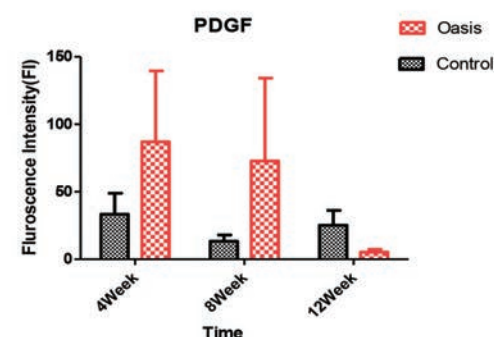
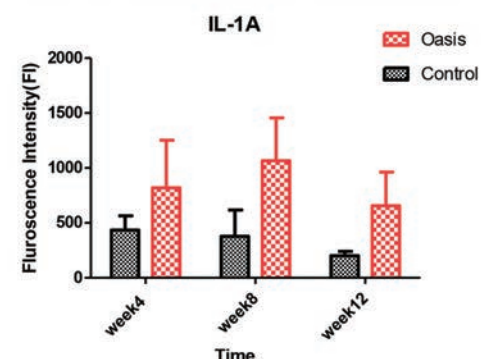


Figure 1. Surgical excision with frozen section of chronic venous ulcer wound, right leg (A). Six weeks after the second application, healed wound at right leg after two Oasis Applications (B).

Healing Rate calculated by using Wound Healing Formula



	Control			Oasis		
	Mean	SEM	N	Mean	SEM	N
Healing Rate	47.665	22.803	4	83.372	5.874	4



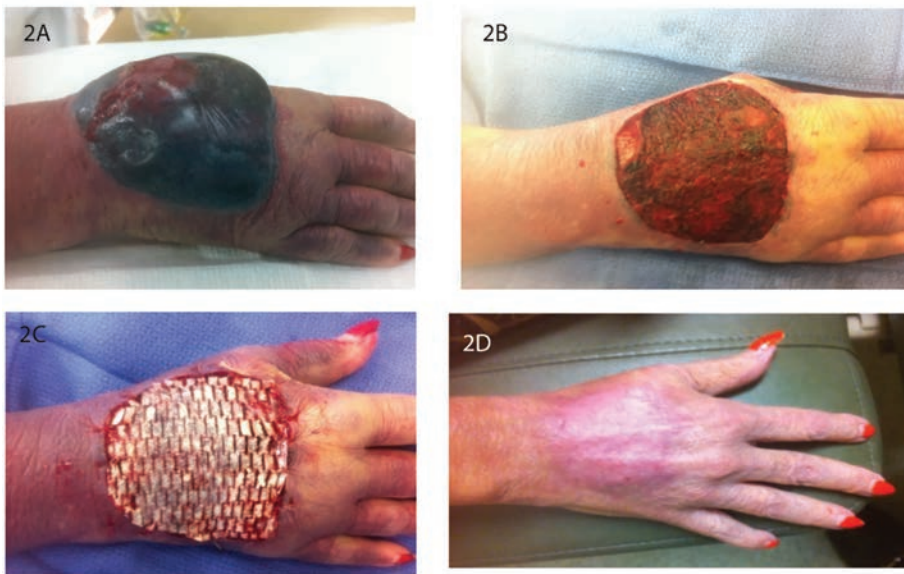


Figure 2. Traumatic hematoma of right hand; patient was on Coumadin (A). Intraoperative view of the right hand after debridement before applying Oasis-Ultra (B). Oasis-Ultra application (C). Healed wound at 4 weeks post Oasis-Ultra application (D).

required to achieve complete healing in 4 weeks. The fourth case involved a patient with a stage IV sacral coccygeal pressure wound. Three months later and after 11 applications of sub-mucosa porcine matrix, his wound healed. The last patient was referred with a 2-year history of chronic venous ulcers at the medial aspect of his right leg. After ruling out malignancy and after 12 applications of the collagen matrix for a period of 3 months, the ulcers showed 80% healing. **Conclusion:** Wounds with different etiologies were successfully treated with porcine intestinal submucosa matrix. By replacing the lost extracellular matrix to guide cellular growth and migration, porcine intestinal submucosa matrix did ultimately speed the healing process.

Abstract 12: Coverage of Exposed Lower Extremity Bypass Vascular Graft with Bi-Laminar Dermal Regeneration Template and NPWT for Limb Salvage

Abdelfatah Abou Issa, MD, Department of Pharmacology and Toxicology, Richard Simman, MD, Department of Pharmacology and Toxicology, Plastic and Reconstructive Surgery, Julie Gilkeson, MD, Vascular Surgery, Wright State University, Boonshoft School of Medicine, Dayton, Ohio

Introduction: A bi-laminar dermal regeneration template is a synthetic skin graft that was developed to treat large burns and to provide coverage of soft tissue defects. It acts as a network for dermal regeneration. Unlike skin grafts, a dermal regeneration template acts as a bridge by which revascularization starts from the terminal part of the bi-laminar dermal regeneration template and gradually spreads out from the edges and covers a non-vascularized lower layer. The advantage of bi-laminar template is to reduce morbidity of the donor site, minimize scar formation and provide coverage of vital structures when flaps are not available.

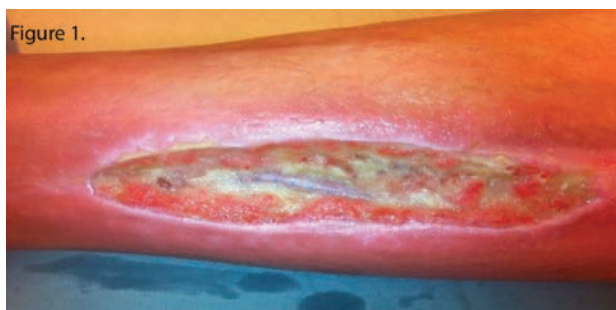


Figure 1. Medial aspect of the right leg with exposed synthetic bypass grafts.

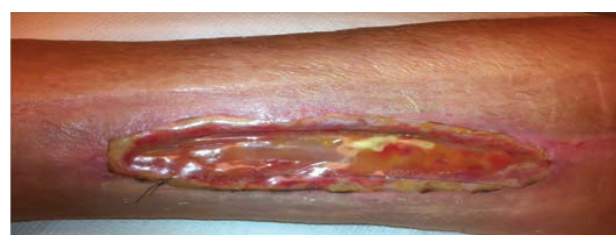

Figure 2. The Integra covering the graft one week post operatively.

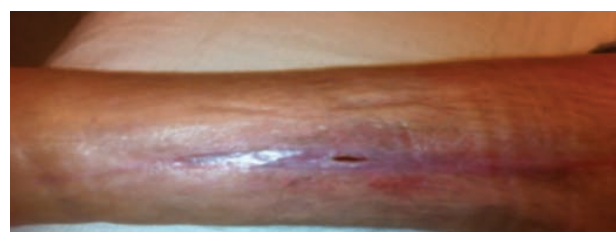


Figure 3. The graft 3 months post operatively with patent bypass graft.

Objective: To cover an exposed lower extremity vascular bypass graft to achieve limb salvage in a patient with no other available options. **Methods:** 56-year-old male with type 2 diabetes, PVD, CAD, and COPD. Status post failed three previous bypass surgeries on his right leg. The third bypass with ringed ePTFE (expanded polytetrafluoroethylene) from the external iliac to a vein patched distal posterior tibialis. Due to severe PVD, the patient wasn't a good candidate for local or free flap coverage. **Results:** The graft remained patent at first 6 months, where it needed distal anastomosis angioplasty to maintain patency. At one year post op, the graft thrombosed and the patient presented with a gangrenous right foot that required a right below-knee amputation. **Conclusion:** Using the bi-laminar dermal regeneration template and NPWT, we were able to achieve limb salvage for a year in a patient with otherwise threatened limb with exposed bypass graft and no other options available.

Abstract 13: The Correlation Between Wound Healing Rate and Circulating Microvesicles Collected from Stage III and IV Pressure Wounds Fluid Treated With NPWT Alone Vs NPWT and Oasis Ultra

Walid Mari, MD, Sara Younes, MD, Sami G. Alsabri, Abdelfatah Shaban, Richard Simman, MD, FACS, FACCWS, Yanfang Chen, PhD, MD, FAHA, David R. Cool, PhD, Terry Oroszi, MS, Wright State University, Boonshoft School of Medicine, Department of Pharmacology and Toxicology, Dayton, Ohio



Figure 2. Small intestinal sub-mucosa (SIS) (Oasis Ultra).

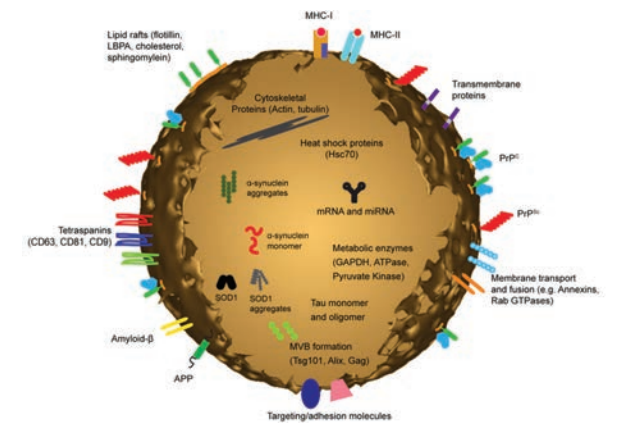


Figure 1. Microvesicle composition.

Figure 1. Microvesicle composition.

Introduction:

Microvesicles (MVs) are cellular membrane fragments ranging from 100 nM to 1000 nM and are shed from almost all cell types. Extracellular MVs play a role in inter-cellular communication by transporting mRNA, miRNA, and other proteins between the cells. Small intestinal sub-mucosa (SIS) (Oasis Ultra Tri-Layer Matrix, Smith & Nephew) is three layers of bio-absorbable extracellular matrix obtained from naturally derived, intact porcine SIS. Our clinical data had shown improved healing rate in the study group. **Objective:** The study has been conducted to investigate if there is any correlation between the extracellular MVs and the rate of wound healing in pressure wounds, which was enhanced in the SIS group. **Materials and Methods:** Wound

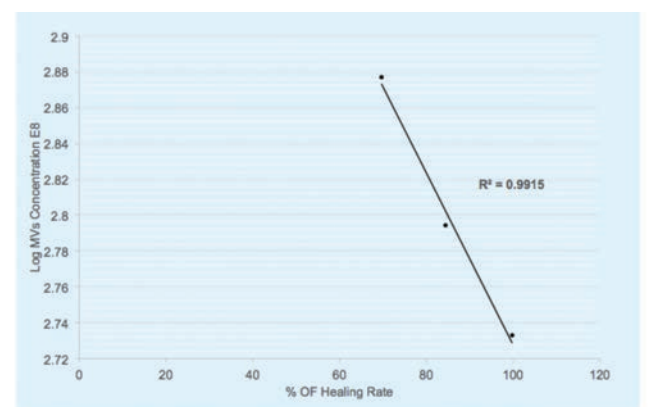


Figure 3. Small intestinal sub-mucosa (SIS) + negative pressure wound therapy (NPWT).

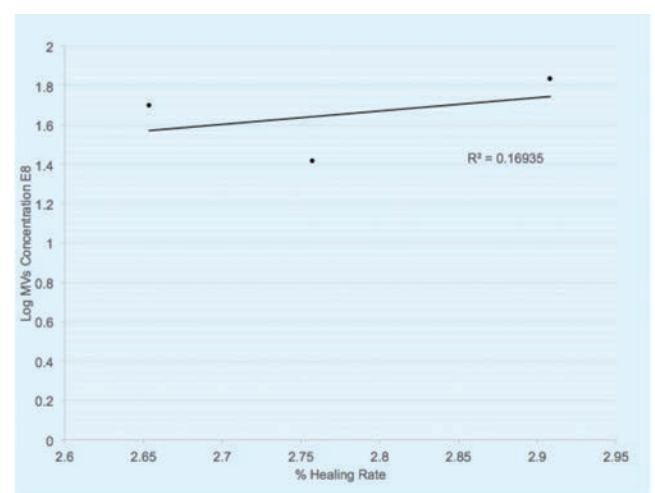


Figure 4. Negative pressure wound therapy (NPWT) alone.

fluid samples were obtained from patients with stage IV trunk pressure ulcers on negative pressure wound therapy (NPWT) with and without SIS dressing. MVs were isolated using an ultracentrifugation method. MVs concentration was measured by a nanoparticle tracking analysis machine (Nanosight). **Results and Discussion:** The obtained result showed that there is a correlation between MVs concentration and wound-healing rate in patients who received combined therapy of SIS plus NPWT. **Conclusion:** SIS could enhance the cells to release more MVs at the earlier stage, which might help to speed up the healing rate.

Abstract 14: Limb Salvage of Complicated Diabetic Patient Using Multiple Contemporary Treatment Modalities and a Team Approach

Alicia Ward, DPM, Podiatry, Guy Pupp, DPM, Podiatry, Patrick Alexander, MD, Interventional Cardiology, Providence Hospital, Farmington Hills, Michigan

A 57-year-old male was referred with a dislocated ankle joint 8 months status post total ankle joint replacement surgery. The patient underwent further surgery to correct underlying deformity and reduction of dislocated ankle joint. Due to noncompliance and multiple comorbidities, the patient failed to heal his incisions and ultimately developed infected wound ulcerations of the left lower extremity, thereby placing him at risk for below-the-knee amputation. **Objective:** To demonstrate the effectiveness of using contemporary treatment modalities and a team approach for limb salvage in a high-risk, complicated patient with insulin-dependent diabetes mellitus, chronic kidney disease, renal transplant, peripheral arterial disease, chronic lymph edema and neuropathy. This case was conducted to establish treatment options that are available aside from a below-the-knee amputation in a complicated high-risk patient with infected non-healing wounds. The patient was treated over a 12-month period on a weekly basis, including office visits and hospital stays. Arterial duplex, CO₂ angiography, Sensilase tissue perfusion testing, bone biopsies, wound cultures, radiographs, and MRI were all used to monitor and evaluate. Treatment modalities included arterial stenting, surgical debridement, graft applications, negative pressure therapy, and both oral and IV antibiotics. With the help of podiatry, interventional cardiology, nephrology, internal medicine, infectious disease, and a wound care team, the patient's limb was salvaged. All wounds have completely healed and adequate ankle joint range of motion was maintained. Arterial studies revealed complete occlusion of the superficial femoral artery. By using CO₂ angiography and stenting, blood flow was restored with no further detriment to patient's failing kidney, thereby eliminating the need for dialysis. By using multiple contemporary treatment modalities in a team approach, limb preservation was possible.

Abstract 15: Non-Invasive Hemodynamics Poorly Predict Disease Severity and Response to Endovascular Therapy in Patients With Critical Limb Ischemia

Jihad A. Mustapha, MD¹; Larry J. Diaz-Sandoval, MD¹; Fadi Saab, MD¹; George Adams, MD²; James Froehlich, MD³; Theresa McGoff, RN¹; Sara Finton, RN¹; Michael R. Jaff, DO⁴; Larry E. Miller, PhD⁵.

¹Metro Heart and Vascular, Wyoming, Michigan; ²Rex Healthcare and University of North Carolina Health Systems, Raleigh, North Carolina; ³University of Michigan, Ann Arbor, Michigan; ⁴Massachusetts General Hospital, Boston, Massachusetts; ⁵Miller Scientific Consulting, Inc., Asheville, North Carolina.

Introduction: Critical limb ischemia (CLI), defined as Rutherford 4-6 with multilevel/multivessel involvement, is end-stage peripheral arterial disease (PAD). Ankle and toe-brachial indices (ABI,TBI), and toe pressure (TP) are used to evaluate PAD and CLI. ABI >0.7,TBI >0.5 and TP >50 mmHg are exclusion criteria in studies of infrapopliteal (IP) CLI therapies. **Objectives:** To determine the reliability of these non-invasive hemodynamic studies (NIHS) to predict disease severity and response to endovascular treatment (EVT) in CLI. **Methods:** The Peripheral RegIstry of Endovascular Clinical OutcoMEs (PRIME) is a prospective, multicenter, outcomes registry focused on minimally invasive EVT for advanced PAD and CLI. The registry enrolled 76 CLI patients who underwent baseline NIHS and IP EVT with 30- to 90-day follow-up NIHS. **Results:** Mean age: 74, 68% male, 67% diabetic. 65% had ABI >0.7, 28% TBI >0.5, and 50% TP >50 mmHg. Three months after successful EVT, limb salvage rates, wound healing and Rutherford class improvement were similar among patients with baseline TP lower or higher than 50 mmHg (*P*=NS). ABI, TBI and TP improved after EVT (0.18 ± 0.08 , *P*<0.001; 0.09 ± 0.08 , *P*<0.05; 12 ± 11 , *P*<0.05, respectively). Based on NIHS, 50-72% of patients would have been excluded from contemporary studies of novel IP CLI therapies. **Conclusion:** NIHS are not useful to discriminate among CLI patients who may benefit from IP EVT. Major revision of currently used inclusion criteria in studies of novel CLI therapies is in order, as many of the patients who might benefit are being excluded.

Note: The PRIME Registry is supported, in part, by unrestricted grants from Bard Peripheral Vascular, Inc., Terumo interventional Systems, Cardiovascular Systems, Inc., Access Closure, Inc., Covidien LP, Boston Scientific Corporation, and Spectranetics Corporation.

Table 1. Predictor of Baseline Disease Severity.

Variable	Rutherford Class	
	IV	V, VI
ABI (DP)	0.77±0.30	0.83±0.41
ABI (PT)	0.78±0.33	0.85±0.39
TBI	0.39±0.20	0.41±0.31
Toe Pressure	59±31	61±48

Values are mean ± standard deviation; DP: dorsalis pedis; PT: posterior tibial.

Table 2. Patients Achieving Rutherford Success (Post Endovascular Treatment) by Baseline Non-Invasive Hemodynamic Studies.

Hemodynamic cutoff data	1+ class improvement	2+ class improvement
Ankle-brachial index (DP)		
≤ 0.7	16 (62) ^a	14 (54) ^a
> 0.7	31 (67) ^b	25 (54) ^b
Ankle-brachial index (PT)		
≤ 0.7	17 (74) ^c	14 (61) ^c
> 0.7	27 (59) ^b	24 (52) ^b
Toe-brachial index		
≤ 0.5	34 (64) ^d	28 (53) ^d
> 0.5	14 (67) ^a	12 (57) ^a
Toe pressure		
≤ 50	23 (62) ^f	18 (49) ^f
> 50	25 (68) ^f	22 (60) ^f

Values are n (%); DP: dorsalis pedis; PT: posterior tibial; ^an=26; ^bn=46; ^cn=23; ^dn=53; ^en=21; ^fn=37

Abstract 16: Chronic Total Occlusion Crossing Based on Cap Morphology (C-TOP) in CLI Patients: A Pilot Study and Interim Analysis of the PRIME Registry.

Fadi Saab, MD¹, Jihad A. Mustapha, MD¹, Larry J. Diaz-Sandoval, MD¹, James Froehlich, MD², Gwennan Engen, RN¹, Carmen Heaney, RN, BSN¹, Eva Kline-Rogers, NP², Larry Miller, PhD³, George Adams, MD⁴

¹Metro Heart and Vascular, Wyoming, Michigan; ²University of Michigan, Ann Arbor, Michigan; ³Miller Scientific Consulting, Inc., Asheville, North Carolina; ⁴Rex Healthcare and University of North Carolina Health Systems, Raleigh, North Carolina.

Introduction: Critical limb ischemia (CLI) is characterized by long, calcified chronic total occlusions (CTOs). Traditional crossing approaches fail in 20-40%. **Objectives:** To analyze CTO cap morphologies and determine if their study can aid in the design




Figure 1. C-TOP classification.

of successful crossing and treatment strategies. **Methods:** CTOs from 100 consecutive patients enrolled in PRIME (a prospective multicenter outcomes registry developed to measure and report on minimally invasive endovascular therapies for advanced PAD and CLI) were retrospectively analyzed and categorized according to their cap morphologies using the “C-TOP classification” (Figure 1). Types of primary arterial access (antegrade, retrograde, femoral, tibialpedal, combined) were studied in a univariate regression model, comparing their frequency and need for additional access (access conversion). Multivariate logistic regression was utilized to analyze predictors of crossing direction (antegrade, retrograde) and need for combined access. **Results:** Mean age: 68 years; Average CTO length: 250mm. CTO Type I (14%), Type II (39%), Type III (14%), Type IV (33%). Primary combined access: 31%. Access conversion: 26%. Retrograde pedal access: 73%. Retrograde crossing: 26%. CTO Type IV: mostly crossed in retrograde fashion (OR=70, $P<0.05$). CTO Type III: mostly approached with combined access (OR=4.3, $P=0.02$). **Conclusion:** This is the first report of CTO cap morphology analysis to guide access and therapy in CLI patients. The CTO classification accurately predicts the successful approach in most cases. Data from this study support the use of retrograde tibial pedal access in complex CTOs and the recommendation to design access and treatment protocols based on CTO cap analysis.

Note: The PRIME Registry is supported, in part, by unrestricted grants from Bard Peripheral Vascular, Inc., Terumo interventional Systems, Cardiovascular Systems, Inc., Access Closure, Inc., Covidien LP, Boston Scientific Corporation and Spectranetics Corporation.

Abstract 17: Tibio Pedal Arterial Minimally Invasive Retrograde Revascularization (TAMI Technique): Initial Findings of the Peripheral Registry of Endovascular Clinical Outcomes (PRIME Registry)

Jihad A. Mustapha, MD¹, Fadi Saab, MD¹, Larry J. Diaz-Sandoval, MD¹, James Froehlich MD², Sara Finton, RN¹, Theresa McGoff, RN¹, Judy Van Dam¹, Eva Kline-Rogers, NP², Larry E. Miller, PhD³, George Adams, MD⁴

¹Metro Heart and Vascular, Wyoming, Michigan; ²University of Michigan, Ann Arbor, Michigan; ³Miller Scientific Consulting, Inc., Asheville, North Carolina; ⁴Rex Healthcare and University of North Carolina Health Systems, Raleigh, North Carolina.

Background: A growing subset of patients with critical limb ischemia (CLI) cannot undergo revascularization procedures using standard techniques, due to anatomical and clinical limitations. The tibio pedal arterial minimally invasive retrograde revascularization (TAMI technique) was designed to overcome this hurdle by the sole utilization of retrograde tibio-pedal access for revascularization. **Objectives:** The purpose was to analyze the effect of TAMI technique on clinical outcomes of patients enrolled in the PRIME Registry. **Methods:** Data were obtained from PRIME (a prospective multicenter outcomes registry developed to measure and report on minimally invasive endovascular therapy for advanced PAD and CLI). 39 patients who underwent TAMI technique were analyzed. Immediate outcomes and complications were evaluated. **Results:** Mean age: 68; 82% males. Most patients (73%) had CLI (Rutherford class \geq IV). Access sites: anterior tibial (50%), posterior tibial (47.5%), dorsalis pedis (2.5%). Mean access attempts: 1.3. Access success rate: 95.2 to 100% (depending

on access site). 56 total lesions were treated (20 femoro-popliteal, 36 tibials). Treatment included balloon angioplasty (14), stenting (5), orbital atherectomy (19), and laser atherectomy (1). Complications were 3 non-flow limiting dissections (7.7%) and 1 perforation (2.6%). No additional complications were noted (including hematoma, arteriovenous fistula, embolism/thrombus, bleeding, pseudoaneurysm, aneurysm, compartment syndrome, amputation, death). Mean length of hospital stay: 0.6 days. **Conclusion:** PRIME is the first clinical registry to follow patients with advanced PAD and CLI. Data from this registry supports the use of the TAMI technique, which results in low complication rates and shortened length of hospital stay. The TAMI technique represents a safe and effective approach in CLI patients.

Note: The PRIME Registry is supported, in part, by unrestricted grants from Bard Peripheral Vascular, Inc., Terumo interventional Systems, Cardiovascular Systems, Inc., Access Closure, Inc., Covidien LP, Boston Scientific Corporation and Spectranetics Corporation.

Abstract 18: Ultrasound-Guided Access in Patients With Critical Limb Ischemia: Initial Findings of the PRIME Registry

Jihad A. Mustapha, MD¹, Fadi Saab, MD¹, Larry J. Diaz-Sandoval, MD¹, James Froehlich, MD², Sara Finton, RN¹, Theresa McGoff, RN¹, Eva Kline-Rogers, NP², Larry Miller, PhD³, George Adams, MD⁴

¹Metro Heart and Vascular, Wyoming, Michigan; ²University of Michigan, Ann Arbor, Michigan; ³Miller Scientific Consulting, Inc., Asheville, North Carolina; ⁴Rex Healthcare and University of North Carolina Health Systems, Raleigh, North Carolina.

Introduction: Critical limb ischemia (CLI) is a complex disease. Current endovascular therapies (EVT) require multiple, “non-traditional” arterial accesses in patients with severely diseased vessels. Ultrasound has been shown to decrease complications related to arterial access. **Objectives:** To analyze immediate outcomes related to the use of ultrasound (US)-guided access in traditional and advanced tibio-pedal access approaches in patients from the PRIME registry. **Methods:** 578 access sites from 407 patients enrolled in the Peripheral Registry of Endovascular Clinical Outcomes (PRIME) (a prospective multicenter outcomes registry developed to measure and report on minimally invasive EVT for advanced peripheral arterial disease (PAD) and CLI) were evaluated. Access distribution/success, immediate outcomes, complications, and length of hospital stay were analyzed. **Results:** Mean age: 70 years; 67% males. Most patients (58%) had CLI (Rutherford class \geq IV). Access approach: antegrade femoral (n=119), retrograde femoral (n=112), dual femoral/tibial (n=77), dual retrograde femoral (n=42), retrograde tibio-pedal (n=39), and other (n=17). Mean number of attempts: 1.3 ± 0.3 . Median access time: 42 ± 14 seconds. Access success: $90 \pm 10\%$.

Table 1. Access Site Complication Rates (406 patients*).

Variable	Femoral Antegrade (n=119)	Femoral Retrograde (n=112)	Dual – Femoral/Tibio-pedal (n=77)	Dual – Femoral Retrograde (n=42)	Tibio-pedal Retrograde – TAMI (n=39)	Other (n=17)
Hospital stay, days **	1.4 (0,1,8)	1.3 (0,1,14)	1.4 (0,1,14)	1.1 (0,1,5)	0.6 (0,0,13)	1.5 (1,1,5)
Death	0	0	0	0	0	0
Hematoma	3 (2.5%)***	0	1 (1.3%)	0	0	1 (5.9%)
Amputation	1 (0.9%)	0	0	0	0	0
Compartment syndrome	0	0	0	0	0	0
Aneurysm	0	0	0	0	0	0
Pseudoaneurysm	2 (1.7%)	0	2 (2.6%)	1 (2.4%)	0	1 (5.9%)
Bleeding	18 (15.1%)	5 (4.5%)	12 (15.6%)	5 (11.9%)	0	3 (17.6%)
BARC1	1	1	1	0	0	0
BARC2	13	4	10	5	0	2
BARC3a	3	0	0	0	0	1
BARC3b	1	0	1	0	0	0
Transfusion	4	0	0	0	0	1
Endovascular intervention	0	0	1	0	0	0
Surgical intervention	1	0	0	0	0	0

*Of 407 patients, unable to obtain access in one patient using femoral retrograde approach

Table 1. Complications With Tibio Pedal Arterial Minimally Invasive Retrograde Revascularization (TAMI Technique) Access.

Variable	TAMI (n=39)
Hospital stay, days *	0.6 (0,0,13)
Death	0
AV fistula	0
Embolism	0
Dissection	3 (7.7%)
Flow limiting	0
Non-flow limiting	3
Hematoma	0
Perforation	1 (2.6%)
Mild	0
Moderate	0
Severe	1
Rupture	0
Spasm	0
Thrombus	0
Amputation	0
Compartment syndrome	0
Aneurysm	0
Pseudoaneurysm	0
Bleeding	0
BARC1	0
BARC2	0
BARC3a	0
BARC3b	0
Transfusion	0
Endovascular intervention	0
Surgical intervention	0

*Not access related.

Complications: hematomas (1.2%), bleeding requiring transfusion/intervention (1.5%), pseudoaneurysm (1.5%), aneurysm (0%), compartment syndrome (0%), amputation (0.2%: not access-related), and death (0%). Shortest length of stay was for tibio-pedal retrograde access alone (0.6 days). **Conclusion:** PRIME is the first clinical registry to follow patients with advanced PAD and CLI. Utilization of US-guided arterial access in this complex cohort carries a high success rate, and a low rate of complications. As therapeutic strategies evolve, these features will be of paramount importance to improve overall clinical outcomes in these patients.

Note: The PRIME Registry is supported, in part, by unrestricted grants from Bard Peripheral Vascular, Inc., Terumo interventional Systems, Cardiovascular Systems, Inc., Access Closure, Inc., Covidien LP, Boston Scientific Corporation and Spectranetics Corporation.

Abstract 19: Below-the-Knee and Visceral Arterial Revascularization Following Acute Ischemia From Thrombo-Embolitic Events Using a Novel Mechanical Thrombectomy System — The PRISM Study Interim Results

George Adams, MD¹, James Benenati, MD², Richard Saxon, MD³, Corey Teigen, MD⁴

¹Director of Cardiovascular and Peripheral Vascular Research, Interventional Cardiology, North Carolina Heart and Vascular Research, Raleigh, North Carolina;

²Interventional Radiology, Baptist Health South Florida, Miami, Florida; ³Interventional Radiology, Tri City Medical Center, Oceanside, California; ⁴Interventional Radiology, Sanford Medical Center, Fargo, North Dakota.

The Indigo System (Penumbra) is a trackable and novel aspiration system indicated for peripheral/visceral arterial thromboembolism. The multicenter PRISM trial set out to assess the safety and efficacy of this system in patients with defined peripheral/visceral arterial occlusions. **Objective:** To determine the safety and efficacy profile of the Indigo system in peripheral/visceral arterial thromboembolism from diverse causes. **Methods:** To date, 55 patients have been enrolled in this retrospective study. Mechanical thromboembolism was performed using the Indigo System in cases of failed thrombolysis, acute ischemia, or complication-related distal emboli. Primary site of occlusion was popliteal (38.9%), superficial femoral (18.5%), peroneal (9.3%), anterior tibial (9.3%), posterior tibial (7.4%), profunda femoris (3.7%), superior mesenteric (3.7%), renal (3.7%), common femoral (1.9%), external iliac (1.9%), and brachial (1.9%) arteries. **Results:** Mean age of patient was 70±13 years. Baseline angiographic TIMI 0/1 was reported in 96.1% of patients. Prior to intervention with the Indigo system, 45.3% of patients had no treatments, 37.7% received thrombolytics, 9.4% received mechanical intervention, and 7.5% received concomitant thrombolytics and mechanical therapies. Median time from symptom onset to intervention was 5.0 days (IQR 2.0–24.0). Following treatment, 96.1% of patients were revascularized to TIMI 2 (39.2%) or TIMI 3 (56.9%). Six patients experienced serious adverse events; none were device-related. **Conclusion:** Clinical experience thus far supports mechanical thromboembolism from aspiration to be safe and effective in the treatment of peripheral/visceral arterial occlusions. High revascularization rates validate application of the Indigo System in the peripheral vasculature.

Abstract 20: A Multidisciplinary Treatment Approach for Chronic Non-Healing Transmetatarsal Amputation Secondary to Calciphylaxis and Peripheral Vascular Disease

Guy Pupp, DPM, Priya Sajja, DPM, Thomas Davis, MD, Rebecca Studinger, MD, St. John Providence Hospital, Detroit, Michigan

Calciphylaxis or calcific uremic arteriolopathy is a rare finding that is commonly associated with end-stage renal disease. This disease primarily starts as erythematous, violaceous mottling which progresses to black eschar, forming non-healing ulcers that often occur in the lower limbs. This process can be complicated with peripheral vascular disease and can result in below-the-knee amputations. We discuss a 56-year-old non-diabetic female with a history of kidney transplant, end-stage renal disease, hemodialysis, peripheral vascular disease and calciphylaxis who presents with a chronic non-healing transmetatarsal amputation site. Multiple consultants recommended below-the-knee amputation. This study demonstrates that with a multidisciplinary approach and the use of contemporary technology, patients have the ability to heal lower extremity wounds. Our team consisted of infectious disease, nephrology, plastic surgery, interventional cardiology and podiatric surgery. The patient underwent multiple endovascular revascularization procedures. Plastic surgery performed a deep epigastric perforator flap graft. Over the next year the podiatry, plastics, and infectious disease team performed routine serial debridements, including the use of orthobiologics and negative pressure wound therapy. The patient successfully healed and is biomechanically optimal to continue her daily activities. Utilizing a tailored team approach and seeking out innovative techniques provides patients the potential to heal complicated lower extremity wounds without the need for major lower limb amputations.

Abstract 21: Use of Low Pressure Diagnostic Angioplasty for Selective Orbital Atherectomy Below-the-Knee and Below-the-Ankle

Julio Sanguily III, MD, Martin Memorial Medical Center, Stuart, Florida

Introduction: Peripheral artery disease (PAD) is a prevalent disorder that affects 18 million Americans. Left untreated, PAD can lead to amputation. The number of amputations performed annually in the U.S. is estimated to be 160,000 to 180,000, and more than 50% of these patients never undergo an arterial evaluation prior to amputation. In the last two decades, the rate of major amputation declined by half. The lower major amputation rates demonstrate that with appropriate treatment strategy, better outcomes can be achieved. **Objectives:** A case presentation of low pressure (<4atm) diagnostic angioplasty for selective (focal) orbital atherectomy system (OAS) treatment of calcified lesions below the knee (BTK) and below the ankle (BTA). **Methods:** A 53-year-old male presented with critical limb ischemia, and 2nd and 4th toe amputations. The patient had a history of diabetes and kidney disease. In areas where the balloon was unable to completely inflate (low pressure diagnostic angioplasty), the OAS device was used to focally treat the lesions prior to final balloon angioplasty. **Results:** Patient presented with critical limb ischemia and baseline angiograms indicated severe blockages and poor blood flow BTK and BTA. Low pressure (<4atm) diagnostic angioplasty enabled targeted/focal OAS treatment of calcified lesions, resulting in improved blood flow BTK and BTA. **Conclusions:** Low pressure (<4atm) diagnostic angioplasty is a novel concept developed to enable targeted/focal treatment and reduced treatment time of calcified lesions using OAS. A larger study would be worthwhile to further analyze the outcomes and cost benefits of such an approach in CLI patients.

Abstract 22: Limb Preservation in the Navajo Nation

Scott M. Brannan, MD, Keith Goss, DPM, Thomas J. Peters, MD, Tuba City Regional Health Care, Tuba City, Arizona

Introduction: American Indian/Alaskan Native groups have rates of diabetes and amputations 2 to 5 and 3 to 4 times higher (respectively) than age-matched cohorts in the general population. The Navajo Reservation is the largest reservation in the U.S., equivalent in size to West Virginia, with 300,418 registered Tribal members. In May 2014, to address the endemic presence of diabetic foot complications in the Navajo Nation, the existing podiatry/orthopedic limb preservation program was augmented with onsite vascular evaluation and intervention. **Objective:** Prospectively monitor outcomes of a multi-disciplinary limb preservation program, including onsite vascular intervention and optimal foot care at an Indian hospital. **Materials and/or Methods:** Patients seen in the podiatry clinic were evaluated for peripheral arterial disease (PAD) with a standard screening form and physical examination. At-risk patients were referred for vascular diagnostic evaluation and discussion by the multidisciplinary limb preservation team. Candidates for revascularization were treated onsite by a specialty trained vascular interventionalist, and followed in the podiatry clinic for ongoing wound care. Clinical endpoints included successful target lesion revascularization, periprocedural or procedural complications, post-procedural morbidity/mortality in first 30 days, and major amputation at six months. **Discussion/Results:** Total vascular interventions: 87. Successful target lesion revascularization: 89%. Major amputations: 1. Mortality: 0. Wound healing: 95%. **Conclusion:** The addition of onsite vascular evaluation and intervention at a native American hospital significantly improved outcomes for healing of diabetic foot wounds and significantly reduced the rate of major amputation.

Clinical experience thus far supports mechanical thromboembolism from aspiration to be safe and effective in the treatment of peripheral/visceral arterial occlusions. High revascularization rates validate application of the Indigo System in the peripheral vasculature.

AMP Meeting

Continued from page 1

to CLI drastically reduced across this country and across the world. We want every physician focused on techniques to save limbs, because we hold the utmost responsibility to care for patients with this very serious disease and help improve and extend their lives.

GAME-CHANGING EDUCATION

Thomas Zeller, MD, interventional cardiologist and director of the department of angiology at Universitaets-Herzzentrum Freiburg-Bad Krozingen, Germany, and AMP course co-director, shared a global perspective on the latest advances, devices, and therapies for critical limb ischemia in his keynote, "Historical Perspective on the Evolution of DCB Therapy: Is the DCB the Holy Grail for CLI Therapy?"

Leading physicians including Dr. D. Chris Metzger, MD, from Wellmont CVA Heart Institute in Kingsport, TN; Dr. Mehdi Shishehbor, DO, from the Cleveland Clinic in Cleveland, OH; and Dr. George Adams, MD, from Rex Healthcare and University of North Carolina Health Systems performed live cases via video stream as expert faculty panels offered discussion and exchange.

Conference education highlights included contributions from nearly 100 faculty, including CLI thought leaders Drs. Thomas Davis, MD, Lawrence Garcia, MD, Michael R. Jaff, DO, Krishna J. Rocha Singh, MD, Robert Beasley, MD, Marianne Brodmann, MD, Ramon Varcoe, MD, Mariano Palena, MD, William Hiatt, MD, Osamu Iida, MD, Lanfroi Graziani, MD, Aljoscha Rastan, MD, and Sven Bräunlich, MD.

This year's conference offered attendees the ability to practice ultrasound guided tibial-pedal access on cadaveric models. AMP faculty member Robert Vorhies, MD, a board certified vascular and endovascular surgeon with Cox Health Systems in Springfield, Missouri, observed, "The cadaver lab is a phenomenal opportunity for attendees to improve their abilities without placing their patients at risk while they learn. It gives them the ability to focus completely on scrutiny, sedation management, and so on." He added, "It also gives the attendee confidence to implement this technique into their practice on day one when they return home."

Next year's AMP Symposium will be held August 10-13, 2016 in Chicago. For more information, visit <http://www.amptheclimeeting.com>.

Upcoming Clinical Events

Transcatheter Cardiovascular Therapeutics (TCT)

San Francisco, CA, United States

October 11-15, 2015

www.crf.org/tct

VIVA 2015: Vascular Interventional Advances

Las Vegas, NV, United States

November 2-5, 2015

www.vivaphysicians.org

VEITHsymposium 2015

New York, NY, United States

Tuesday, November 17, 2015 to Saturday, November 21, 2015

www.veithsymposium.org

The VERVE Symposium in Conjunction with LINC Australia

Sydney, Australia

December 3-5, 2015

www.vervesymposium.com

Leipzig Interventional Course (LINC) 2016

Trade Fair Leipzig, Leipzig, Germany

January 26 – 29, 2016

<http://www.leipzig-interventional-course.com/>

Toe to Toe Transcatheter Solutions: 4TS International Conference

Conrad Dubai, Dubai, United Arab Emirates

February 18-19, 2016

4tsconference.com

THE GLOBAL EDUCATION COURSE FOR VASCULAR MEDICINE AND INTERVENTION

VIVA 15

SAVE THE DATE

NOVEMBER 2-5, 2015

WYNN LAS VEGAS

WWW.VIVAPHYSICIANS.ORG

Come early and get MORE from your VIVA Experience!

(October 31 - November 1, 2015)



Registration Now Open!

15


A New Day in CLI Treatment

Spectranetics now provides a new approach to complex cases of CLI by offering differentiated and unique technologies for treating the full-spectrum of CLI disease below-the-knee – Quick-Cross™ to cross stubborn occlusions, laser atherectomy with the Turbo-Elite™ to vaporize long, diffuse atherosclerotic lesions and AngioSculpt™ to power through severe calcium deposits.


Turbo-Elite™
Laser Atherectomy Catheter


Quick-Cross™
Support Catheter

AngioSculpt®



**CROSS
PREP
TREAT**

IMPORTANT SAFETY INFORMATION
See complete IFU for more information.

© 2014 Spectranetics. All rights reserved.
Approved for external distribution. D024079-00 102014